

Prevalence of skin lesions in common bottlenose dolphins (*Tursiops truncatus* (Montagu, 1821)) in the Central Adriatic Sea

Ujčić, Korina

Master's thesis / Diplomski rad

2021

Degree Grantor / Ustanova koja je dodijelila akademski / stručni stupanj: **University of Zagreb, Faculty of Science / Sveučilište u Zagrebu, Prirodoslovno-matematički fakultet**

Permanent link / Trajna poveznica: <https://um.nsk.hr/um:nbn:hr:217:047710>

Rights / Prava: [In copyright](#)/[Zaštićeno autorskim pravom.](#)

Download date / Datum preuzimanja: **2024-08-07**



Repository / Repozitorij:

[Repository of the Faculty of Science - University of Zagreb](#)



University of Zagreb
Faculty of Science
Department of Biology

Korina Ujčić

**Prevalence of skin lesions in common
bottlenose dolphins (*Tursiops truncatus*
(Montagu, 1821)) in the Central Adriatic
Sea**

Master thesis



Zagreb, 2021.

Sveučilište u Zagrebu
Prirodoslovno-matematički fakultet
Biološki odsjek

Korina Ujčić

**Učestalost kožnih lezija kod dobrog dupina
(*Tursiops truncatus* (Montagu, 1821)) u
srednjem Jadranu**

Diplomski rad

Zagreb, 2021.

This master thesis was made at the Blue World Institute of Marine Research and Conservation in Veli Lošinj under the guidance of Asst. Prof. Draško Holcer, PhD, from the Croatian Natural Museum in Zagreb and at the Department of Biology of the Faculty of Science in Zagreb under the guidance of Asst. Prof. Zoran Marčić, PhD. The thesis is submitted to the Department of Biology at the Faculty of Science of the University of Zagreb for the purpose of acquiring a title/degree of Master in Ecology and Nature Preservation.

Acknowledgements

I would like to thank my mentors and supervisors - Draško, Maša, Jure and Grga. Thank you for your patience and help with this thesis, but also for everything else you have taught me since I have joined the Blue World team.

A big thank you to my university mentor, Asst. Prof. Zoran Marčić, for the support with finalizing my thesis.

Lošinj crew, I have enjoyed every moment spent with you and am grateful for everything I have learned and the experience I have gained while working with you. Jerry, you have been a great support, a cheerful friend, and always here to help and thank you for that. All the wonderful moments on the sea, in the office, and in the apartment, and quite a few amazing friendships make the time spent with the Blue World team on Vis and Lošinj truly precious. I genuinely appreciate the opportunity you have given me to learn and grow with you.

John, your belief in me, your words, and your love have been the biggest encouragement I could have wished for. Thank you for setting an incredible example for me.

Mama, tata i Mateo, vama posebno i najveće hvala na strpljenju i podršci u svim mogućim oblicima kroz sve ove godine studiranja. Hvala što ste vjerovali u mene.

Još jedno poglavlje je iza nas.

TEMELJNA DOKUMENTACIJSKA KARTICA

Sveučilište u Zagrebu
Prirodoslovno-matematički fakultet
Biološki odsjek

Diplomski rad

Učestalost kožnih lezija kod dobrog dupina (*Tursiops truncatus* (Montagu, 1821)) u srednjem Jadranu

Korina Ujčić

Rooseveltova trg 6, 10000 Zagreb, Hrvatska

Podaci prikupljeni metodom foto-identifikacije za 35 jedinki običnog dobrog dupina (*Tursiops truncatus*, Montagu 1821) opaženih na području Viškog arhipelaga od 2014. do 2018. preuzeti su iz baze podataka Instituta Plavi svijet s ciljem istraživanja učestalosti kožnih lezija. Prema vidljivim obilježjima i opisima iz literature, unaprijed je definirana 21 kategorija lezija. Istraženi su učestalost i položaj lezija kroz vrijeme kako bi se dobio uvid u njihov obim, promjene kroz vrijeme i trajnost. Ispitano je postoje li veze između kategorija te mogu li lezije zabilježene na leđnoj peraji biti dovoljne za procjenu učestalosti lezija na ostalim dijelovima tijela. Lezije su zabilježene kod 29 (82,86%) jedinki i zabilježeno je 15 kategorija, od kojih su najučestalije bile blijede fleke, fleke s tamnim prstenom, lezije na tragovima nastalim grebanjem zubima i „tetovaže“. Nisu pronađene značajne veze među kategorijama. Veća učestalost lezija zabilježena je na lateralnim nego na dorzalnim dijelovima tijela. Rezultati su pokazali da leđna peraja nije dobar pokazatelj učestalosti lezija. Od 205 zabilježenih slučajeva lezija, 49 (23,9%) se s vremenom povuklo. Zabilježena trajnost lezija je varirala. Ulegnuća, ožiljci, bijele fleke i fleke omeđene bijelim prstenom su zabilježene kroz najdulji period. Promjene u izgledu zabilježene su kod „tetovaža“, fleka s tamnim prstenom i blijedih lezija.

(62 stranice, 41 slika, 4 tablice, 47 literaturnih navoda, jezik izvornika: engleski)

Rad je pohranjen u Središnjoj biološkoj knjižnici

Ključne riječi: foto-identifikacija; kožne promjene; vidljive karakteristike; trajnost lezija;

Viški arhipelag

Voditelj: doc. dr. sc. Draško Holcer

Suvoditelj: doc. dr. sc. Zoran Marčić

Ocjenitelji:

Doc. dr. sc. Zoran Marčić

Doc. dr. sc. Petar Žutinić

Izv. prof. dr. sc. Petar Kružić

Rad prihvaćen: 7.7.2021.

BASIC DOCUMENTATION CARD

University of Zagreb
Faculty of Science
Department of Biology

Master Thesis

Prevalence of skin lesions in common bottlenose dolphins (*Tursiops truncatus* (Montagu, 1821)) in the Central Adriatic Sea

Korina Ujčić

Rooseveltova trg 6, 10000 Zagreb, Croatia

Photo-identification data of 35 common bottlenose dolphins (*Tursiops truncatus*, Montagu 1821) encountered in Vis archipelago from 2014 until 2018 were acquired from the Blue World Institute database to investigate the prevalence of skin lesions. According to their appearance and descriptions from available literature, 21 predefined lesion categories were used. The prevalence of lesions over time and the body areas affected were studied to assess their extent, progression, and duration. Association between lesion categories was investigated, as well as the viability of using lesions on the dorsal fin as a proxy for assessing the prevalence of lesions on other parts of the body. Lesions were found in 29 (82.86%) of the studied individuals and 15 lesion categories were recorded, of which the most common were pale skin patches, dark-fringed spots, rake mark associated, and tattoo-like lesions. No significant associations were found between the lesion categories. More lesions were recorded on the sides of the body than on the dorsal parts, and the results implied that the dorsal fin is not a reliable proxy for lesion prevalence. Of 205 lesion occasions recorded, 49 (23.9%) retreated. The observed longevity of lesions varied. Progression was observed for tattoo-like and pale lesions, and dark-fringed spots.

(62 pages, 41 figures, 4 tables, 47 references, original in: English)

Thesis is deposited in Central Biological Library.

Keywords: photo-identification; epidermal conditions; visible features; lesion longevity; Vis archipelago

Supervisor: Asst. Prof. Draško Holcer, PhD

Co-supervisor: Asst. Prof. Zoran Marčić, PhD

Reviewers:

Asst. Prof. Zoran Marčić, PhD

Asst. Prof. Petar Žutinić, PhD

Assoc. Prof. Petar Kružić, PhD

Thesis accepted: 7.7.2021.

Table of Contents

List of abbreviations.....	vii
1. Introduction	1
1.1. Common bottlenose dolphin.....	1
1.2. Bottlenose dolphin in the Adriatic Sea	2
1.3. Skin lesions in cetaceans	3
1.4. Aims and objectives.....	6
2. Research area: Vis archipelago	7
3. Material and methods	8
3.1. Data sampling	8
3.2. Photo analysis	9
3.3. Skin lesion categories	11
3.4. Data analyses	17
3.4.1. Skin lesions prevalence in sample	17
3.4.2. Co-occurrence of different skin lesion categories	18
3.4.3. Skin lesion prevalence and extent in relation to affected body area.....	18
3.4.4. Dorsal fin as a proxy for skin lesions on the entire body.....	19
3.4.5. Skin lesion progression, duration, and healing rate	19
4. Results	20
4.1. Data sampling	20
4.2. Photo analysis	21
4.3. Skin lesion categories	22
4.4. Data analyses	26
4.4.1. Skin lesion prevalence in sample.....	26
4.4.2. Co-occurrence of different skin lesion categories	29
4.4.3. Skin lesion prevalence and extent in relation to affected body area.....	32
4.4.4. Dorsal fin as a proxy for lesions on the entire body	40
4.4.5. Skin lesion progression, duration, and healing rate	41
5. Discussion	54
6. Conclusion.....	58
7. References	59

List of abbreviations

Ant_d: anterior dorsal
Ant_v: anterior ventral
Aped_d: anterior peduncle dorsal
Aped_v: anterior peduncle ventral
BWI: Blue World Institute of Marine Research and Conservation
CONR: concentric rings
DEPRESSED: depressed and sunken
DFC: dorsal fin collapse
DFS: darks-fringed spot
FIN: dorsal fin
HWI: half-weight index
HYPER: hyperpigmented
HYPO: hypopigmented
LOBOMYCOSIS: lacaziosis/lobomycosis-like
LV: large vesicular
Mid_d: middle flank dorsal
Mid_v: middle flank ventral
ORANGE: orange patches
PALE: pale skin patch
PENNELLA: *Pennella balaenopterae* and associated scars
PETRO: *Petromyzon marinus* and associated scars
Post: posterior peduncle
RAKE: rake mark associated
SCAR: healing wound scar
SV: small vesicular
SWD: small white dots
TATTOO: tattoo-like lesion
Vent: ventral peduncle
WFF: white fin fringe
WFS: white-fringed spot
WS: white spot

1. Introduction

1.1. Common bottlenose dolphin

The common bottlenose dolphin, *Tursiops truncatus* (Montagu, 1821) belongs to the family Delphinidae, order Cetacea. It is a cosmopolitan species (Figure 1) which resides in the coastal and pelagic waters in the temperate and tropical zones (Wells and Scott, 2009). Two ecotypes exist, inhabiting shallow coastal or deep offshore waters. Among the three species within the genus *Tursiops* Gervais 1855, only *T. truncatus* is found in the Mediterranean and the Adriatic Sea and further use of the name bottlenose dolphin will refer to that species only.

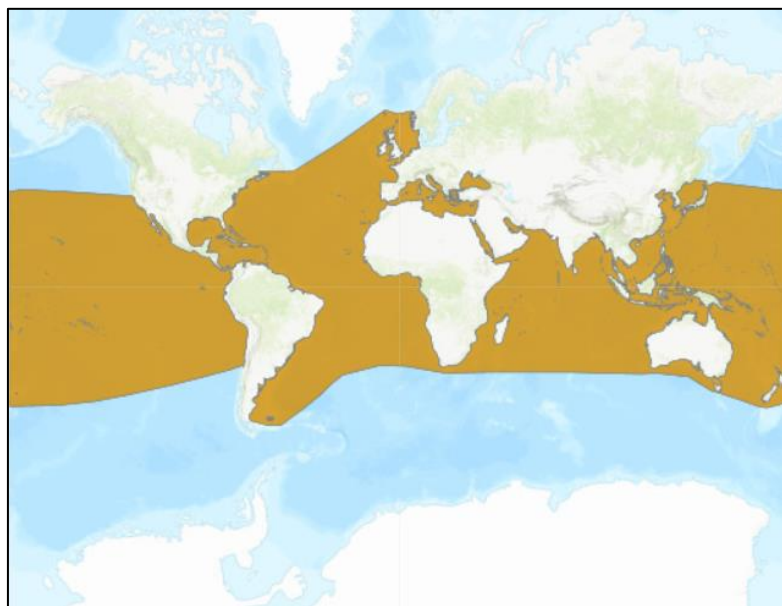


Figure 1. Distribution of the common bottlenose dolphin (*T. truncatus*). (<https://www.iucnredlist.org>. Downloaded on 20.1.2021.)

By comparing the natural markings on and near their dorsal fins, individual dolphins can be identified (Würsig and Würsig, 1977, Würsig and Jefferson, 1990). Notches on the dorsal fin and the shape of the fin, coloration and pigmentation patterns of the fin and the upper body, scratches, tooth rakes and other wounds can all be useful for identifying individuals (Würsig and Jefferson, 1990). The most identifiable feature is the trailing edge of the fin as it accumulates the most apparent and durable features, cuts, nicks, notches, and scars (Würsig and Würsig, 1977). The notches and cuts give the fin a recognizable imprint on both sides of the fin even in poor lighting and they do not heal. Thus, they are considered as "primary markings" for identification (Pleslić et al., 2018). Other features on the fin and body, such as tooth rakes and discolorations, which might not always be visible but can be used to identify individuals, are considered as "secondary markings" (Pleslić et al., 2018).

Bottlenose dolphins have a robust body, ranging from 2.5 to 3.8 m in length (Wells and Scott, 2009). Their coloration varies from dark grey on the back, lighter grey on the side to a white ventral part (Holcer, 2012). Males were found to live up to 48 years, while females can live to more than 57 years (Wells and Scott, 2009). During the reproductive years, females have calves with different males and a calf stays with the mother for 3 to 6 years (Wells and Scott, 2009). Bottlenose dolphins are opportunistic feeders, feeding mostly on different species of fish and cephalopods (Wells and Scott, 2009).

1.2. Bottlenose dolphin in the Adriatic Sea

The bottlenose dolphin is the most studied marine mammal species in the Adriatic. A continuous research of a single resident bottlenose dolphin community in the Mediterranean Sea has been conducted since 1987 in the Cres-Lošinj Archipelago. It is the longest ongoing study of a single community in the Mediterranean. Moreover, Holcer et al. (2015) found that the bottlenose dolphin is the only cetacean species that permanently inhabits the whole Adriatic. According to the Red Book of Mammals of Croatia (Holcer, 2006), the common bottlenose dolphin is categorized as an “endangered” species. The species is protected by the Croatian Nature Protection Law (NN 80/13) and listed under Annexes II and IV of the European Union Habitats Directive.

Based on aerial surveys conducted in 2010 and 2013 (Fortuna et al., 2018), the estimated uncorrected abundance of bottlenose dolphins in the Adriatic was 5,700 animals (95% CI = 4,300-7,600), while the estimated number for North Adriatic was 2,600 animals (95% CI = 2200-2,900), for Central Adriatic 1,100 animals (95% CI = 800-1,500), and for South Adriatic 1,800 animals (95% CI = 1,500-2,400). Though, these abundance estimates were rounded to the nearest hundred and are underestimated as they were not corrected for availability and perception bias (i.e., animals that were diving and not visible or were on the surface but missed by observers). More recently and according to the ACCOBAMS Survey Initiative report (ACCOBAMS, 2021), the abundance of common bottlenose dolphins in the Adriatic Sea was estimated to 10,350 (CV=0.2916; 95% CI = 5,896-18,166) animals based on aerial surveys conducted in 2018. This estimation was gained after fitting the detection function (and taking into account the perpendicular distance to the sightings and additional variables that might have affected the ability to observe animals) and right truncating perpendicular distance data. The aerial surveys they conducted have shown once again that the Adriatic Sea, especially the

northern part, is an important habitat for bottlenose dolphins. Comparing the referent catalogues of identified individuals from Cres-Losinj archipelago, North Dalmatia, and Vis area showed that in each of these areas lives a different community, although, some individuals were seen in multiple research areas (Pleslić et al., 2020).

Research of the bottlenose dolphin community inhabiting Vis archipelago and the surrounding area started in 2007 (Holcer, 2012). By 2020, 1,085 individuals were identified from photo-identification data collected during boat surveys (Frleta-Valić and Miočić-Stošić, 2021). Based on data collected from 2008 until 2018, the estimated size of the local community, corrected for the proportion of non-distinctive individuals, was between 353 (95% CI: 287-483) and 600 (95% CI: 462-866) animals (Miočić-Stošić et al., 2019). Research showed that this area is an important habitat for the local community of bottlenose dolphins.

The Adriatic Sea is a semi-enclosed basin (Cushman-Roisin et al., 2007). It is considered shallow, as most of its area is less than 200 meters deep, especially its northern part with an average depth of 30 m. The central sub-basin, where Vis research area spans, is defined by a 100 m bathymetric line on the north and 170 m deep Palagruža sill in the south. Jabuka Pit sits between the two sills, with two depressions and reaching 273 m in its deepest point. The average sea surface temperature in the Central Adriatic ranges from around 13°C in the winter to around 24°C in the summer (Penzar et al., 2001). Water salinity is around 38 PSU (Grbec and Precali, 2009).

1.3. Skin lesions in cetaceans

Various skin lesions have been documented in bottlenose dolphins and numerous other cetacean species worldwide (Bearzi et al. (2009); Geraci et al. (1979); Hupman et al. (2017); Maldini et al. (2010); Pettis et al. (2011); Ramos et al. (2018); Taylor et al. (2020)). Photographs taken during photo-identification studies are an efficient and widely used tool for documenting the presence, prevalence and visual characteristics of skin anomalies (Thompson and Hammond (1992); Wilson et al. (1999); Hupman et al. (2017)). Some of these lesions include rake marks gained during interactions with conspecifics, scars from entanglement or attachment of ectoparasites, changes in natural skin pigmentation or ulcerations. Studies in which tissue samples of the affected areas were provided have confirmed the presence of infectious pathogens in certain lesions (Geraci et al. (1979); Hart et al. (2012); Smith et al. (1983); Van Bresseem et al. (1994)). This provided a link between lesion appearance and causation which

can be used as a reference point for visual assessment of skin anomalies. Those and other studies which included histological examination relied on data obtained from animals held in captivity, bycaught or stranded animals. However, only samples from live or fresh stranded animals could be used to determine the cause of lesions (Wilson et al., 1999). Since such sampling is mostly unachievable during regular research, photo-identification data provide an attainable and non-invasive mean of assessing skin conditions in free-ranging marine mammals (Hart et al., 2012). Although this method does not reveal the cause of lesions, conditions can be visually described and categorized according to their visual features, such as size, shape, color, and texture.

Among most documented conditions, “tattoo skin disease” has been well described and has been linked to cetacean poxvirus. These skin lesions can vary in appearance and have been described as “pinhole” lesions (multiple light grey stippled lesions, with dark centers or borders), “ring”, “circle” and “tattoo” lesions (may be a consolidation of the pinhole lesions) (Townsend and Staggs, 2020). By analyzing tissue samples, Geraci et al. (1979) found that “ring lesions” and “tattoo lesions” are different stages of poxvirus infection: pale lesions (which may have dark borders) were early stage, lesions with grey centers were intermediate stage, and lesions with dark punctiform centers (with or without light borders) were advanced stage. In black punctiform areas of these lesions, desquamated cells, cellular debris, and bacteria were found. Those dark punctiform centers may form a stippled pattern which is then called “tattoo”. Smith et al. (1983), Van Bresseem et al. (1994) and Van Bresseem and Van Waerebeek (1996) have also confirmed poxvirus from “tattoo” lesions. On the other hand, Hart et al. (2012) analyzed samples of “spotted”, “dark-fringed”, and “tattoo-like” lesions and all samples were negative for poxvirus and herpesvirus. However, evidence suggestive of a viral infection has been revealed. Through health assessment of dolphins held in the captivity, Geraci et al. (1979) found that poxvirus infection is connected to the general health of the animal and to environmental conditions (poor water quality and sudden change in water temperature from 21°C to 3°C, and they suggested that these lesions may be useful for visual assessment of general health in dolphins. The appearance of lesions caused by poxvirus can vary, lesions can retreat fully or leave faint traces, and can reoccur.

Tissue samples of areas affected by lesions categorized as “pale”, “cloudy” and “white fringed” tested positive for herpesvirus (Hart et al., 2012). “Pale” lesions and loss of pigmentation can occur from numerous factors: may also be a stage of a healing process of prior skin trauma or scarring, a site where ectoparasite has been attached, or may indicate inflammation or prior viral infection, illness, changes in environmental parameters or toxins

(Hart et al. (2012); Sanino et al. (2014); Townsend and Stags (2020)). Hypopigmentation can occur as smaller or larger patches, regionally or on the whole body. Moreover, herpesvirus has also been isolated from “black dots”, as reported in Van Bresseem et al. (1994). Likewise, Smith et al. (1983) have linked vesicular lesions with calcivirus.

In addition to results presented by Geraci et al. (1979), Wilson et al. (1999) also reported that latitude, water temperature, salinity and UV radiation showed a significant effect on the severity of lesions, while only water temperature and salinity showed a significant effect on the prevalence of skin lesions (higher levels of disease related to low water temperature and low salinity). On the other hand, organochlorine compounds (CBs and DDT) and trace metals (Cd, Hg, Pb and Zn) showed no relationship with prevalence or severity, although it was pointed out that sample size was small for those analyses (Wilson et al., 1999). Hart et al. (2012) also found a significant association between occurrence of skin lesions and water temperature and salinity and have reported the increased odds of dark-fringed, tattoo-like, and vesicular lesions occurrence with decrease in water temperature and salinity. However, they have suggested that lesion occurrence is influenced by other factors as well, that lesions manifest with delay after being exposed to colder water temperature, or that occurrence is higher in a particular temperature range.

Until now, few studies on skin lesions have been carried out in the Adriatic Sea. Wilson et al. (1999) analyzed photos taken during the 1990's in Kvarnerić area and found a 74% prevalence of skin lesions in a sample of 50 animals. They found a 44% prevalence of dark lesions (characterized by areas of hyperpigmentation; 50 sampled animals), 41,4% of pale lesions (characterized by areas of hypopigmentation; 58 sampled animals), 10,3% of other lesions (including orange patches, swellings, and patches with a blue-grey sheen; 58 sampled animals), and 98,6% of injuries (including nicks in the edges of the dorsal fin, tooth scratches, irregular wounds and abraded fin tips; 73 sampled animals), while physical deformities (including bending of the dorsal fin and spinal deformations) and external parasites were not recorded (73 sampled animals for each lesion). On the other hand, in a study on tattoo skin lesions, Van Bresseem et al. (2009) analyzed photos from the northern Adriatic Sea (Slovenia) taken between 2002 and 2006 and found a 0% prevalence of tattoo skin lesions in a sample of 80 free-ranging bottlenose dolphins. Miočić-Stošić et al. (2020) have recently studied the occurrence of sea lamprey *Petromizon marinus*, and related scars in 1,491 bottlenose dolphins encountered between 2007 and 2017 in North Dalmatia and Vis archipelago in Central Adriatic Sea. They found eight skin marks related to sea lamprey attachment on five individuals. In

additional bottlenose dolphin individual, they confirmed the attachment of a sea lamprey. This interaction was corroborated by photographs taken in 2014, between Mljet and Korčula islands.

The bottlenose dolphin communities in the Adriatic have been studied for more than 30 years, however, knowledge on skin lesions affecting these communities is still scarce.

Since photo-identification techniques have been used extensively for studying these communities (Holcer (2012); Miočić-Stošić et al. (2019); Pleslić et al. (2019); Pleslić et al. (2020)), the large database of the Blue World Institute could be of great value in assessing the skin condition of bottlenose dolphins inhabiting this area.

1.4. Aims and objectives

Although the population of bottlenose dolphins in the Adriatic Sea has been continuously studied for more than 30 years, there is scarce information on the presence of skin lesions in bottlenose dolphins. The main objective of this study was to gain the first insight into the prevalence of various skin lesions in resident bottlenose dolphin communities in the area around Vis Island, Central Adriatic. To achieve this, the intention was to investigate:

- (1) which categories of skin lesions are present in resident bottlenose dolphins and which are more common,
- (2) whether there is any association or co-occurrence of different lesions,
- (3) what are the differences in the prevalence of skin lesions in relation to different body areas,
- (4) can the dorsal fin be used as a proxy for the presence of skin lesions throughout the body,
- (5) how do skin lesions progress, how long do they last, and what is the rate of healing,
- (6) can any of the external conditions be considered as a baseline for assessing the fitness of a population,
- (7) can any of the external conditions be used as a permanent secondary mark for identifying individuals.

2. Research area: Vis archipelago

Vis Island is the farthestmost inhabited island in the Adriatic Sea. It is located in the open sea of the Central Adriatic, about 50 kilometers from the Croatian mainland and about 145 kilometers from the Italian coast. The study area encompassed the Vis archipelago and Vis Channel (Figure 2). On the north and east side, it was bounded by islands Šolta, Hvar and Korčula, while on the west and south it extended towards the open sea encompassing islands Jabuka, Saint Andrija, Biševo and Sušac. The study area encompasses approximately 5,000 km² (Miočić-Stošić et al., 2015). Depths in the open sea of the Central Adriatic mostly range between 150 and 200 meters (Krstulović Šifner et al., 2009). The study area is located between the two deepest areas in the Adriatic – the Jabuka Pit and South Adriatic Pit, and is under the influence of factors from both areas (Russo and Artegiani, 1996). Due to the direction of water circulation in the surface and deeper layers, the impact of pollution coming from land is minimal (Marasović et al., 2006). With no industrial facilities on the island and no surface water flowing into the sea, the pollution impact from island Vis is also limited. Predominating habitat types in this area are circalittoral fine sand and circalittoral fine mud (Krstulović Šifner et al., 2009).

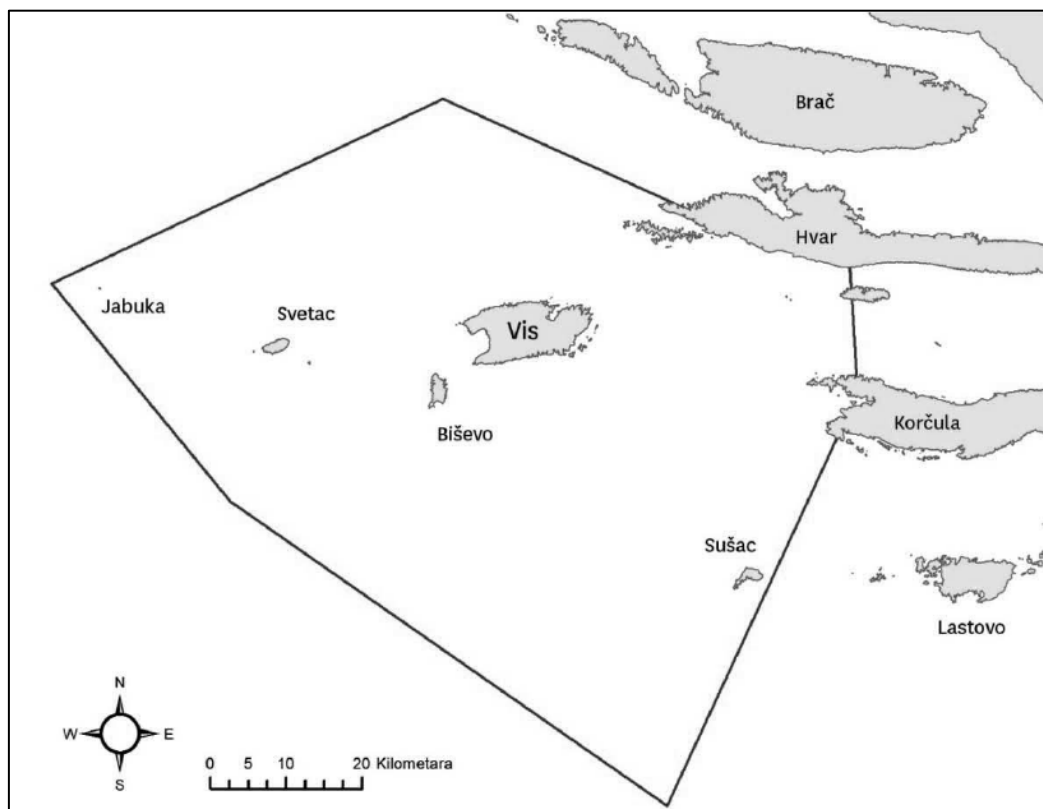


Figure 2. The study area. The core study area encompassed Vis archipelago and included islands Biševo, St. Andrija, Brusnik, Sušac, and Vis Channel. Image taken from Miočić-Stošić et al. (2015).

3. Material and methods

3.1. Data sampling

Data used in this research comprised photo-ID data from 2014 to 2018 acquired from the Blue World Institute's database. Data were collected during dedicated boat based surveys within Vis research area throughout spring and summer months (mostly between May and September), following the standard methods described in Miočić-Stošić et al. (2015) and Pleslić et al. (2015). Photographs of bottlenose dolphins were captured with digital cameras with the emphasis on their dorsal fins, but the rest of the body was also photographed whenever possible. All photographs had been analyzed following the photo-identification method as described in Miočić-Stošić et al. (2015) and Pleslić et al. (2015) and were acquired together with corresponding metadata which included sighting data (date, time, location), name or code of the animal in the photo, gender (if known), side of the body captured (RD – right dorsal, LD – left dorsal), and fin code, age class, and quality of the photo as described in Table 1.

Individuals and photographs suitable for skin lesion analysis were filtered out by applying the following criteria:

- 1) Individual was encountered in at least four out of five years during the study period.
- 2) Individual was categorized as at least poorly, fairly, or highly marked and thus recognizable.
- 3) Individual was captured in at least eight sightings during the study period and fair or high-quality photos were obtained.

Additionally, all sightings that did not contain at least one fair or high-quality photo were excluded from the dataset.

Using the listed criteria, 35 identified individuals were selected from the database. 33 of them were adults from the beginning of the study, while two were juveniles in 2014 and became adults (first time seen without their mothers) in 2017. Eight adults were females (seen with calves either during the research period or in the years before) and one was confirmed to be male, while the gender of the other dolphins remained unknown.

Table 1. Age classes, fin codes and levels of photo quality as described in *Miočić-Stošić et al. (2015)* and *Pleslić et al. (2015)*.

Age class	Age class description
A (adult)	Body is 2.8 – 3.2 m long, dark grey with nicks and notches on the dorsal parts of the body, and especially on the fin.
J (juvenile)	Body length is 2/3 of the adult's body, light grey with fewer nicks and notches on dorsal parts of the body; encountered in the group with the mother but does not necessarily swim next to her.
C (calf)	Body length is 1/2 of the adult's body, light grey coloration; always seen swimming next to the mother.
N (newborn)	Body length is 1/3 of the adult's body, dark grey coloration often with fetal stripes; always seen swimming next to the mother.
Fin code	Fin code description
UM (unmarked)	Dorsal fin with no primary or secondary markings, common for young individuals.
PM (poorly marked)	Only few small nicks on the trailing edge of the dorsal fin.
FM (fairly marked)	Several nicks and notches of various sizes on the dorsal fin.
HM (highly marked)	Many nicks or notches on the fin, white coloration due to many scars, general shape of the fin is often changed.
Quality level	Quality level description
PQ (poor quality)	Dorsal fin is not in focus, not perpendicular to the camera lens, not of good size, and/or most distinguishing features are not visible.
FQ (fair quality)	Dorsal fin is in focus, perpendicular to the camera lens, there is no water spray, and most distinguishing features are visible.
HQ (high quality)	Dorsal fin is in focus, perpendicular to the camera lens, and is well lit, there is no water spray, and all details are visible.

3.2. Photo analysis

Digital images were screened for lesion presence using Adobe Photoshop Lightroom Classic software which allows users to organize photographs and enter relevant data linked to each photo. With a plugin specially created for this purpose, new custom fields were created to record visible body parts and lesion types for each analyzed photo (Figure 3).

Following Hupman et al. (2017), the dolphin body was divided into sectors named and abbreviated as follows: dorsal fin (fin), anterior (ant), middle-flank (mid), anterior peduncle (aped), posterior (post), head (head), jaw (jaw), throat (throat), chest (chest), belly (belly), ventral (vent) and fluke (fluke). Due to the dominant surfacing behavior, which predominantly allows for capturing the dorsal fin and dorsal parts of the body only, three sectors (anterior, middle-flank and anterior peduncle) were additionally divided into 'dorsal' and 'ventral' sectors, thus being replaced with anterior dorsal (ant_d), anterior ventral (ant_v), middle-flank dorsal (mid_d), middle-flank ventral (mid_v), anterior peduncle dorsal (aped_d) and anterior

peduncle ventral (aped_v). This finally resulted in 15 body sectors for each lateral side of the body shown in Figure 4.

Only photos in which any part of the animal's body was well-lit, in focus, perpendicular and reasonably close to the camera (animal's body takes approximately 1/16 of the photo) were considered reliable and used for the analysis to avoid false positive or negative errors. Although some of these photographs did not meet the listed criteria to be considered as fair or high-quality photo in photo-identification, in this study a reliable photo was not limited by features of the dorsal fin only, but rather by clarity of any body part, provided that the fin/individual was confidently recognizable.

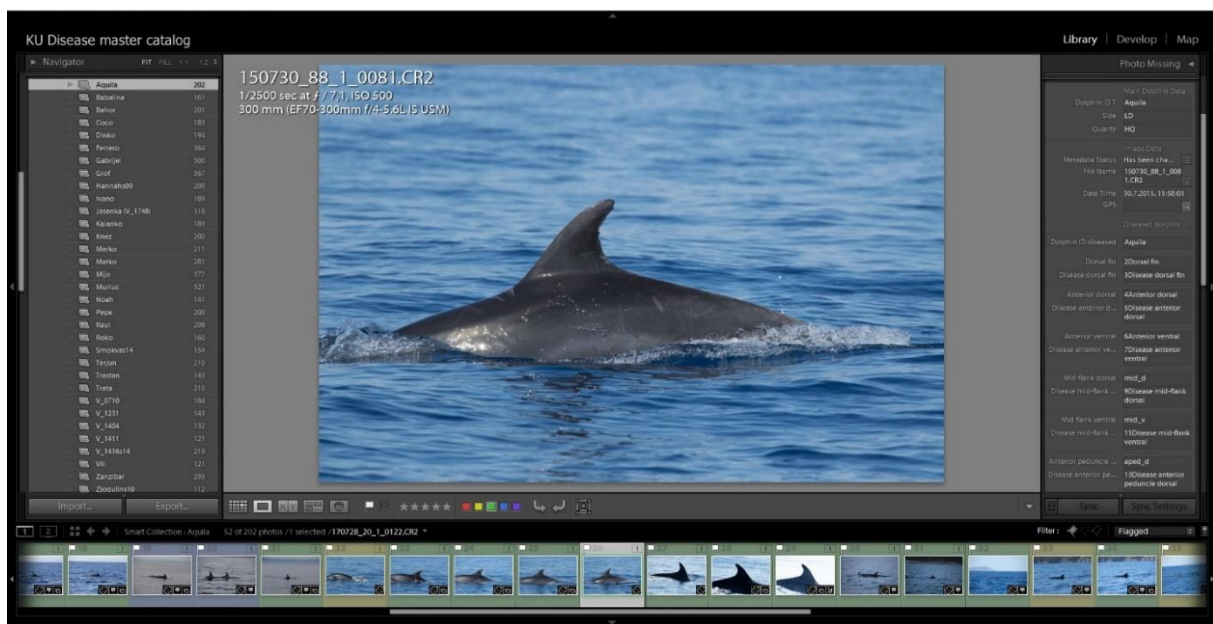


Figure 3. A screenshot of Adobe Photoshop Lightroom Classic software working space. The left pane displays smart collections containing images of individuals, while the right pane displays fields for entering metadata.

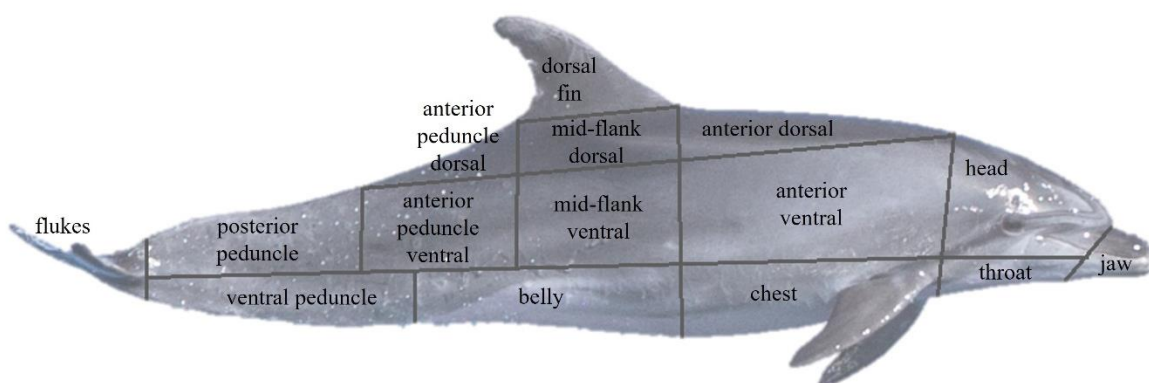


Figure 4. Common bottlenose dolphin with 15 body sectors defined (adapted from *Hupman et al. (2017)*).

In every photo, visible sectors were noted and, whenever a lesion was present, the lesion category was noted under the body sector affected. The extent of the lesion within each sector was not assessed. If different lesion categories were present or multiple sectors were affected and visible in the same photo, each lesion category was assigned to the appropriate body sectors. Sectors were considered as visible when at least 75% of their respective area was captured either in a single photo or as a cumulative combination of multiple photos from the same sighting, or when a lesion was recorded on it. To keep track of temporal progression of lesions, photos were analyzed with respect to capturing date. All marked lesions were checked and confirmed by another experienced researcher from BWI. Any lesion which could not be classified was deemed inconclusive and removed from further analysis.

3.3. Skin lesion categories

For this research, 21 categories of skin lesions were predefined according to described features and images in the published literature. Since it was not possible to define the etiology of skin lesions via biopsies, lesions were categorized visually based on their shape, size, color, and texture. Categorization and referent criteria for determination of lesion categories were defined based on descriptions and images from Bertulli et al. (2012), Bossley and Woolfall (2014), Gonzalvo et al. (2015), Hart et al. (2012), Hupman et al. (2017), Leone et al. (2019), Miočić-Stošić et al. (2020), Ramos et al. (2018), Sanino et al. (2014), Stack et al. (2019), Van Bresseem et al. (2015), and Wilson et al. (1997), while additional categories, which had been observed on multiple occasions in the BWI database, were defined based on visual features. If a lesion could not be classified into any of the predefined categories, it was not recorded. Name and abbreviation, description, references, and referent image for each lesion category are shown in Table 2.

Table 2. Predefined categories of skin lesions with abbreviations, descriptions, references, and referent images. All referent images were taken from the BWI's database, unless indicated otherwise.





Category and abbr.	Description	Referent image
CONCENTRIC RINGS (CONR)	A black dot surrounded by alternating concentric rings of hyper- or hypopigmentation. (Adapted from Hupman et al. (2017))	 <p>(Image adapted from Hupman et al. (2017))</p>
DARK-FRINGED SPOTS (DFS)	Small and mostly circular, white spots, surrounded by a dark halo. They were mostly flat or slightly raised. A dark border could be difficult to see on darker skin so they might be difficult to distinguish from small white lesions. (Adapted from Hupman et al. (2017); Wilson et al. (1997))	
DEPRESSED AND SUNKEN (DEPRESSED)	Depressed or sunken areas of variable sizes and shapes. This included ulcers, erosions, and contracted scars. (Adapted from Hupman et al. (2017))	
DORSAL FIN COLLAPSE (DFC)	Bending of a dorsal fin to one side. (Adapted from Stack et al. (2019))	 <p>(Image adapted from Stack et al. (2019))</p>

Table 2 Continued.






Category and abbr.	Description	Referent image
HEALING WOUND SCAR (SCAR)	Fibrous tissue that replaced normal skin, possibly developed while a wound was healing. (Adapted from Hupman et al. (2017))	
HYPER-PIGMENTED (HYPER)	Small, circular, uniformly black lesions with poorly or well-defined border. Lesions are flat and mostly appear as assemblages of black freckles, but can also appear as larger, clumped lesions. (Adapted from Hart et al. (2012), Hupman et al. (2017), and Wilson et al. (1997))	
HYPO-PIGMENTED (HYPO)	Amorphous patches or flecks lighter than the surrounding skin; may appear as whitish, light gray or dark gray area, chalky, poorly defined and without a darker border. Lesions were flat and of any size. (Adapted from Hupman et al. (2017), and Wilson et al. (1997))	
LACAZIOSIS/LOBOMYCOZIS-LIKE (LOBOMYCOSIS)	Multiple, ulcerated cutaneous nodules forming whitish, light gray to slightly pink, verrucous lesions of various sizes; can extend over wide areas. (Adapted from Ramos et al. (2018) and Van Bresseem et al. (2015))	 <p data-bbox="975 1496 1382 1570">(Image adapted from Ramos et al. (2018))</p>
ORANGE PATCH (ORANGE)	A patch of orange discoloration while the skin remains intact. (Adapted from Hart et al. (2012), and Hupman et al. (2017))	 <p data-bbox="959 1921 1398 1995">(Image adapted from Hupman et al. (2017))</p>

Table 2 Continued.




Category and abbr.	Description	Referent image
PALE SKIN PATCH (PALE)	Skin patches that lost their normal pigmentation and have a whitish or light gray coloration. The patches differed in size and shape but had rounded and distinctive borders. (Adapted from Sanino et al. (2014))	
<i>Pennella balaenopterae</i> + SCARS (PENNELLA)	The presence of <i>Pennella balaenopterae</i> was recorded if it was captured on the photograph. Scars that were assumed to be the remains of the attachment were linear wounds and holes with swollen edges, but without previous observation of the parasite attached to that spot, it could not be confirmed. (Adapted from Bertulli et al. (2012) and Leone et al. (2019))	
<i>Petromyzon marinus</i> + SCARS (PETRO)	Either sea lamprey attachment was directly observed, or characteristic bite marks were believed to have been caused by sea lamprey: a circular or oval-shaped patch with multiple rows of whitish tooth marks; or a wound surrounded by a white, circular coloration. Parallel white rake traces associated with the initial bite marks were sometimes visible and assumed to be a result of sliding of the parasite over the skin. (Adapted from Bertulli et al. (2012) and Miočić-Stošić et al. (2020))	

Table 2 Continued.




Category and abbr.	Description	Referent image
RAKE MARK ASSOCIATED (RAKE)	Hypopigmented or white area associated with rake marks; although rake marks themselves were not considered in this study, development of hypopigmentation in surrounding area was noted.	
SMALL WHITE DOTS (SWD)	Well-defined, white freckles densely spread across a wide area of the body or localized on few body sectors. (Adapted from Hart et al. (2012) and Gonzalvo et al. (2015))	
SUNBURN (SUNBURN)	Severe wounds with granulations and necrosis; yellow or brown discoloration of ulcerative tissue; necrotic epidermis, dermis or blubber might be visible as a white layer; border of the wound might be darker than the normal skin. If observed in later stages, after nodules regress, the tissue might be risen and pale gray, or only white scars could be seen. (Adapted from Bossley and Woolfall (2014))	 <p data-bbox="997 1657 1364 1724">(Latter two images taken from Bossley and Woolfall (2014))</p>

Table 2 Continued.







Category and abbr.	Description	Referent image
TATTOO-LIKE (TATTOO)	Dark or light gray patches variable in size, flat or slightly depressed, with stippled surface and well-defined borders; mostly not uniformly round or uniformly colored. Patches could have a thin dark border. (Adapted from Hupman et al. (2017) and Sanino et al. (2014))	
VESICULAR - SMALL VESICULAR (SV) AND LARGE VESICULAR (LV)	Cutaneous nodular or vesicular lesions, ulcers, pustules and small or large lumps; the color and texture of raised lesions may or may not differ from the surrounding skin. (Adapted from Hart et al. (2012), Hupman et al. (2017), and Wilson et al. (1997))	
VIGGLY (VIGGLY)	Irregular white or black lines on the skin. Lines are more or less curved and could not be associated with bite marks.	
WHITE FIN FRINGE (WFF)	Abraded skin mostly near the top or on the leading edge of the dorsal fin but could be found elsewhere on the body; irregular in shape, but with well-defined borders; large white or pink areas. (Adapted from Gonzalvo et al. (2015) and Wilson et al. (1997))	

Table 2 Continued.

Category and abbr.	Description	Referent image
WHITE SPOTS (WS)	Circular and well-defined white patches of various sizes; flush lesions with smooth surface.	
WHITE-FRINGED SPOTS (WFS)	Small, mostly circular, normally colored, or dark spots surrounded by a white halo; lesions are flush with the skin and smooth. (Adapted from Hart et al. (2012), Hupman et al. (2017), and Wilson et al. (1997))	

3.4. Data analyses

Once all photographs were screened for lesions, all relevant data were exported from Adobe Lightroom and analyzed in Microsoft Excel and SOCPROG 2.8 software.

3.4.1. Skin lesions prevalence in sample

The prevalence of skin lesions was calculated as the percentage of animals in the sample affected by any lesion category at any point in time during the whole study period and as the percentage of animals in the sample affected by each lesion category separately. The same was then calculated for each year of the study period. Percentage of animals for which data were not available were also noted for each year. These results were then used to determine if any of the external conditions could be considered as indicators of a population's compromised fitness.

3.4.2. Co-occurrence of different skin lesion categories

The percentage of animals affected by a varying number of lesions throughout the whole study period was calculated, as well as for each year separately.

To test whether any of the lesions recorded in sampled animals show association or co-occurrence, a cluster analysis was conducted using the SOCPROG 2.8 software. The half-weight index (HWI) was used as a measure of association strength between two lesion categories and was calculated to represent the proportion of occasions in which any two lesion categories were associated (observed on the same dolphin), ranging from '0' if the two lesions were never recorded on the same animal, to '1' if on each animal with one lesion recorded, the paired lesion was also recorded. HWI's asset is its resilience to bias caused by potential incomplete sampling. For this analysis, each animal was considered affected by a certain type of lesion if the lesion was recorded at any point in time during the study period. To explore the division of lesions into groups, the hierarchical analysis was run on the HWI matrix using the average linkage method. To visually represent the division on a dendrogram, the HWI value at which the modularity (Q) was maximized was used as a cut-off. A modularity of 0.3 or above is considered to represent a meaningful division. The cophenetic correlation coefficient was calculated to examine how accurately the association index matrix was represented by the dendrogram. Generally, a cophenetic correlation coefficient of 0.8 or above is considered to indicate good representation.

3.4.3. Skin lesion prevalence and extent in relation to affected body area

For each skin lesion type, data on the affected body sector was also noted. If at least 75% of the body sector was visible, it was denoted as with or without a lesion. The prevalence of each lesion category was calculated for each body sector and the number of sectors affected by each lesion category was counted. Moreover, the overall proportion of lesion occasions was calculated for each body sector. A lesion occasion refers to one lesion category recorded on one body sector, irrelative of its extent. The presence of a lesion was noted as the same occasion from its initial observation onward, until the healing of the category on the respective sector was observed, or more recent photographs of the sector were not available. If more than one sector on the same individual was affected by the same lesion category, a distinct occasion was noted for each of those sectors. Likewise, if one dolphin had the same lesion category on the same body sector on both lateral sides of the body, each was counted as a distinct occasion.

3.4.4. Dorsal fin as a proxy for skin lesions on the entire body

To determine if prevalence of lesions on the dorsal fin alone could be used as a proxy for assessing the prevalence on other body sectors and the total prevalence in the sample, for each affected individual data have been separated to show whether a lesion category occurred on the dorsal fin only, another body sector only, or on both the dorsal fin and another body sector. Proportions of lesions within these three groupings were used to consider if photographs of the dorsal fin only could be sufficient for estimating skin lesion prevalence in bottlenose dolphin communities.

3.4.5. Skin lesion progression, duration, and healing rate

When feasible, a minimum and a maximum possible duration of each lesion occasion was calculated. An occasion was considered healed when the body sector it had affected was observed afterwards and none of the lesions which comprised a particular occasion were visible. For lesions which have been recorded in multiple sightings, the minimum duration was calculated as the number of days from the initial observation until the last date on which a particular occasion was recorded. If the body sector affected by a particular lesion has been recorded prior to the appearance of the lesion occasion and again after it has retreated, a maximum possible duration of the occasion was calculated as the number of days between the sightings showing unaffected body sectors. Since lesions could have appeared at any point in time between two observations showing a difference (unaffected/affected) and likewise, could have retreated at any point in time between the last lesion occasion and the first sighting in which it was no longer present, the minimum and maximum possible durations calculated this way mean each occasion could have lasted for any number of days between the calculated minimum and maximum. Lesions were considered continuous between two sightings, unless significant difference was noted, irrespective of the time elapsed. Lesions recorded in photographs from one sighting only were not included in this analysis unless the photographs of an unaffected body sector were available both prior and after the lesion occasion. The duration of lesions was used to determine if any of the external conditions could be considered as permanent secondary marks for identifying individuals.

4. Results

4.1. Data sampling

During the study period, from 2014 until 2018, the 35 sampled animals were captured in 25,438 photographs, of which 2,075 (8.16%) were of sufficient quality for skin lesion screening and were included in the dataset. A relatively larger number of photographs have been taken in 2015 than in other years and, correspondingly, significantly more photographs were available to be included in the dataset (Figure 5). This was also the only year in which all 35 dolphins from the sample were encountered and available for the analysis. On the other hand, in 2014 only 25 individuals were available for the analysis. Although initial data sampling was designed to include photos from sightings containing at least one fair quality photo of the sampled individual, some sightings had to be excluded as none of the photos met the necessary quality level for assessing skin conditions. Consequently, for 4 individuals, photographs from less than 8 sightings could be used for the assessment - 7 sightings for 3 individuals and 6 sightings for 1 individual. Moreover, for 2 individuals, photographs from only 3 research years were of adequate quality to be assessed. Final numbers of dolphins screened for skin lesions are 25 in 2014, 35 in 2015, 28 in 2016, 32 in 2017, and 31 in 2018.

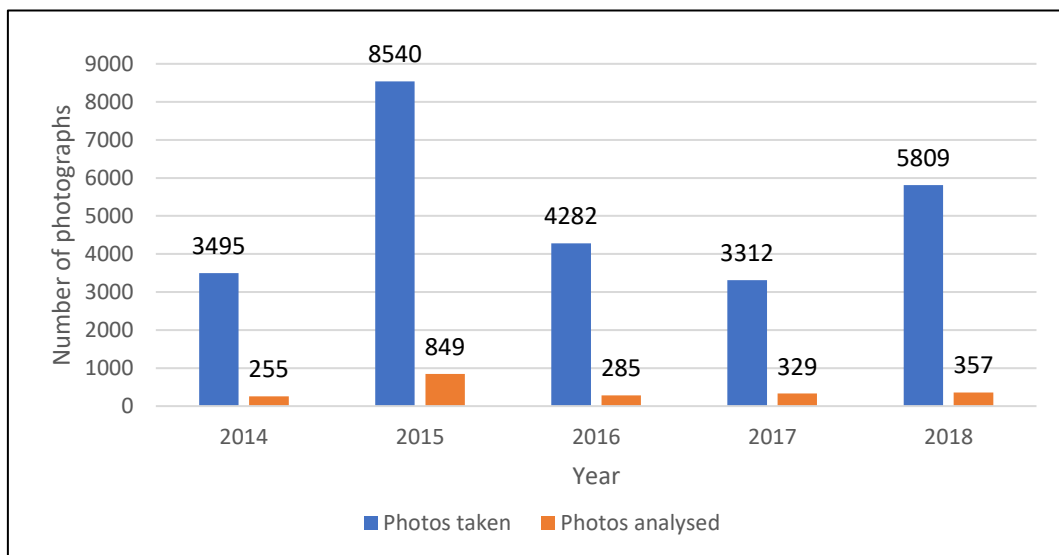


Figure 5. Number of photographs representing sampled animals in each study year. Numbers of available and used photographs are shown.

4.2. Photo analysis

Body sectors regularly recorded on photographs were dorsal fin, anterior dorsal and ventral, middle-flank dorsal and ventral, anterior peduncle dorsal and ventral, posterior peduncle, head, and jaw (Figure 6). Five remaining sectors (throat, chest, belly, ventral, and fluke) were seen notably less frequently than other sectors (Figure 7) and never with lesions, thus were excluded from further analysis. Furthermore, the greatest amount of data within a year was collected in 2015, when all sectors were captured in a notably greater rate than in other years. This coincides with the higher number of photographs taken during 2015 and having captured all individuals in the sample. In that year, no bias was evident towards any individual or body area, but rather greater parts of individuals' bodies were captured overall within the sample.

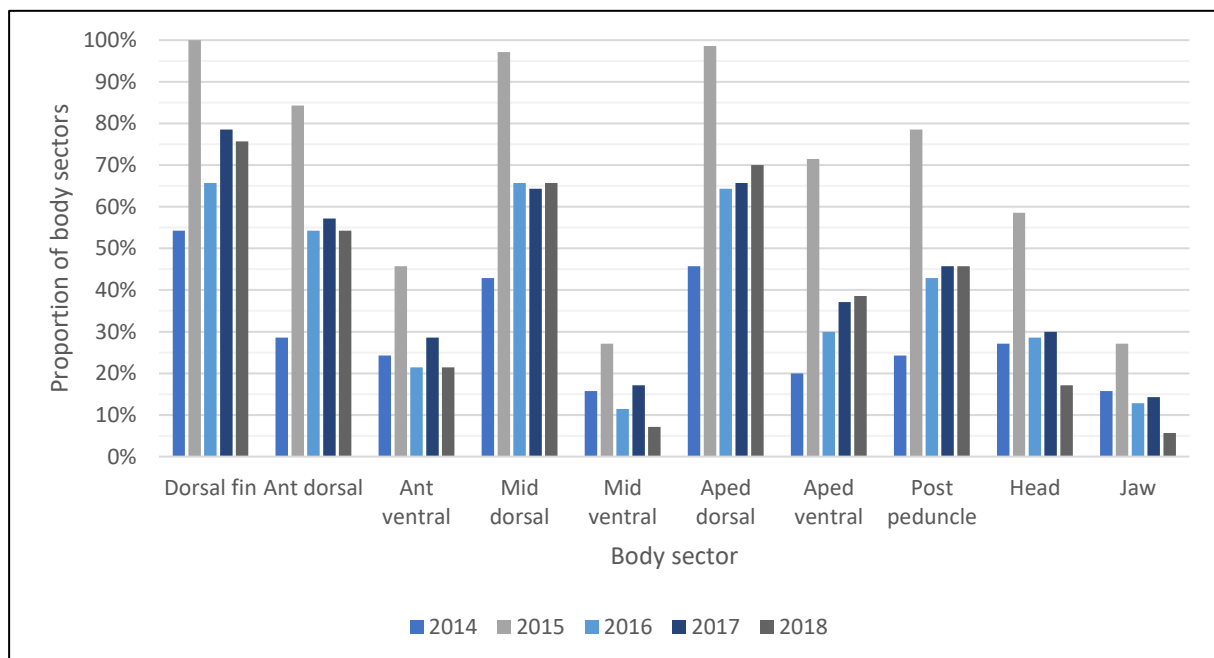


Figure 6. Visibility of regularly captured body sectors through years. Body sector was counted on each lateral side of the animal separately each time it was marked as visible, or if less than 3/4 of it was visible, but a lesion was recorded on it.

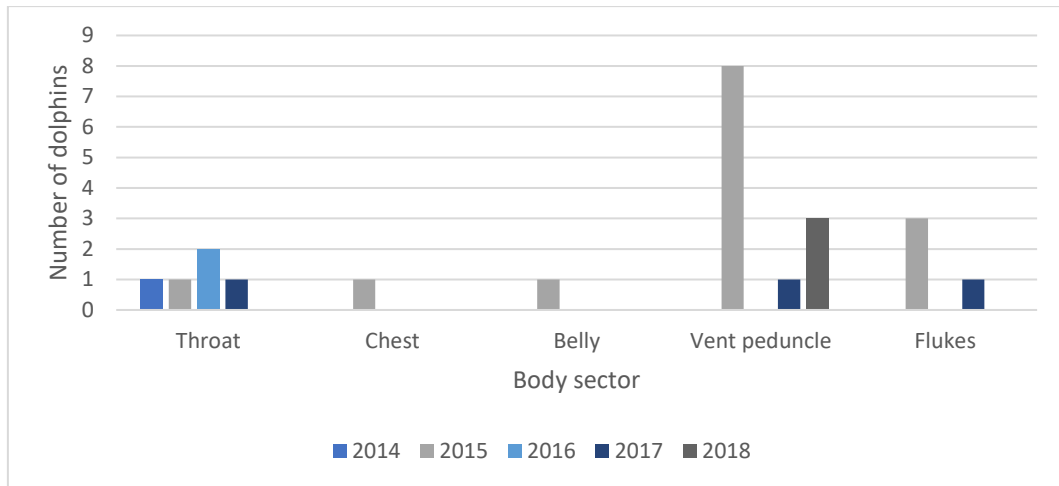


Figure 7. Visibility of less regularly captured body sectors through years. Body sector was counted on each lateral side of the animal separately each time it was marked as visible, or if less than 3/4 of it was visible, but a lesion was recorded on it.

4.3. Skin lesion categories

Skin lesion categories found in the dataset are dark-fringed spots, depressed and sunken, healing wound scar, hyperpigmented, hypopigmented, orange patch, pale skin patch, *Petromyzon marinus* scars, rake mark associated, small vesicular, small white dots, tattoo-like, viggly, white-fringed spots, and white spots. Lesion categories which were not recorded in sampled individuals are concentric rings, dorsal fin collapse, large vesicular, lobomycosis-like, presence of *Pennella balaenopterae* or associated scars, sunburn, and white fin fringe. Examples of lesions recorded in the sample are shown in Figure 8 and Figure 9, while the overview of individuals and skin lesions which affected them is shown in Table 3.




Figure 8. Categories of skin lesions observed during this study: dark fringe spot (a, b), hypopigmented (c, g), tattoo-like (d, e), hyperpigmented (e, g; indicated by yellow arrows), depressed and sunken (f), pale skin patch (h, j), orange patches (i, j; indicated by yellow arrows).




Figure 9. Categories of skin lesions observed during this study: sea lamprey associated scars (a, b), viggly (c, e), healing wound scar (d), white-fringed spots (f), small vesicular (g), rake mark associated (h), white spots (i).

Table 3. List of individuals and lesions which affected them throughout the study period. "CLEAN" refers to individuals with none of the lesions recorded.

Dolphin ID	CLEAN	DEPRESSED	DFS	HYPER	HYPO	ORANGE	PALE	PETRO	RAKE	SCAR	SV	SWD	TATTOO	VIGGLY	WFS	WS	No. of lesions
Aquila			DFS								SV					WS	3
Babalina		DEPRESSED	DFS			ORANGE		PETRO	RAKE				TATTOO	VIGGLY	WFS		8
Bahor			DFS						RAKE		SV					WS	4
Coco		DEPRESSED															1
Dinko					HYPO				RAKE					VIGGLY	WFS	WS	5
Ferrero							PALE		RAKE		SV		TATTOO		WFS	WS	6
Gabrijel											SV			VIGGLY			2
Grof				HYPER	HYPO				RAKE				TATTOO				4
Hannahs09									RAKE								1
Ivano			DFS				PALE	PETRO			SV		TATTOO	VIGGLY			6
Jasenka	CLEAN																0
Kalanko									RAKE		SV					WS	3
Knez				HYPER							SV						2
Marko			DFS						RAKE				TATTOO				3
Matko			DFS						RAKE	SCAR			TATTOO		WFS		5
Mijo					HYPO												1
Murluc		DEPRESSED					PALE						TATTOO				3
Noah							PALE										1
Pepe	CLEAN																0
Raul						ORANGE	PALE		RAKE			SWD				WS	5
Roko			DFS														1
Smokvas14														VIGGLY			1
Terjun			DFS				PALE			SCAR							3
Trastan										SCAR	SV				WFS		3
Trata							PALE								WFS		2
V_0710					HYPO		PALE										2
V_1231	CLEAN																0
V_1404	CLEAN																0
V_1411												SWD		VIGGLY	WFS		3
V_1416s14							PALE						TATTOO	VIGGLY	WFS		4
Vili	CLEAN																0
Zanzibar				HYPER			PALE						TATTOO		WFS		4
Zjogulins10	CLEAN																0
Zoran		DEPRESSED	DFS		HYPO			PETRO			SV						5
Zvir			DFS				PALE						TATTOO				3

4.4. Data analyses

4.4.1. Skin lesion prevalence in sample

Within the dataset, at least one of the predefined lesion categories was found in 29 individuals (82.86%), while in remaining 6 individuals (17.14%) none of those lesions were recorded in visible body areas.

Most common lesion was PALE, found in 11 individuals (31.43%), followed by DFS, RAKE and TATTOO, each found in 10 individuals (28.57%), and SV and WFS, each found in 9 individuals (25.71%). VIGGLY, WS, HYPO and DEPRESSED were found in 7 (20%), 6 (17.14%), 5 (14.29%) and 4 (11.43%) individuals, respectively. HYPER, PETRO and SCAR were found in 3 individuals (8.57%) each, and ORANGE and SWD were found in 2 individuals (5.71%) each (Figure 10). Concentric rings, dorsal fin collapse, large vesicular, lobomycosis-like lesions, presence of *Pennella balaenopterae*, sunburn, and white fin fringe have not been recorded within the present study.

In 2014, lesions were recorded in 14 (40%) individuals. In 2015, the highest number of affected dolphins was recorded - 27 individuals (77.14%). In 2016 and 2017, lesions were recorded in 18 (51.43%) and 17 (48.57%) dolphins, respectively, and in 14 (40%) dolphins in 2018 (Figure 11). Because all sampled individuals were photographed in 2015 and overall more good quality photographs were taken capturing greater areas of individuals' bodies, more occasions of lesions were recorded during that year, with pale skin patches and tattoo-like lesions being more prominent than in the other years (Figure 12).

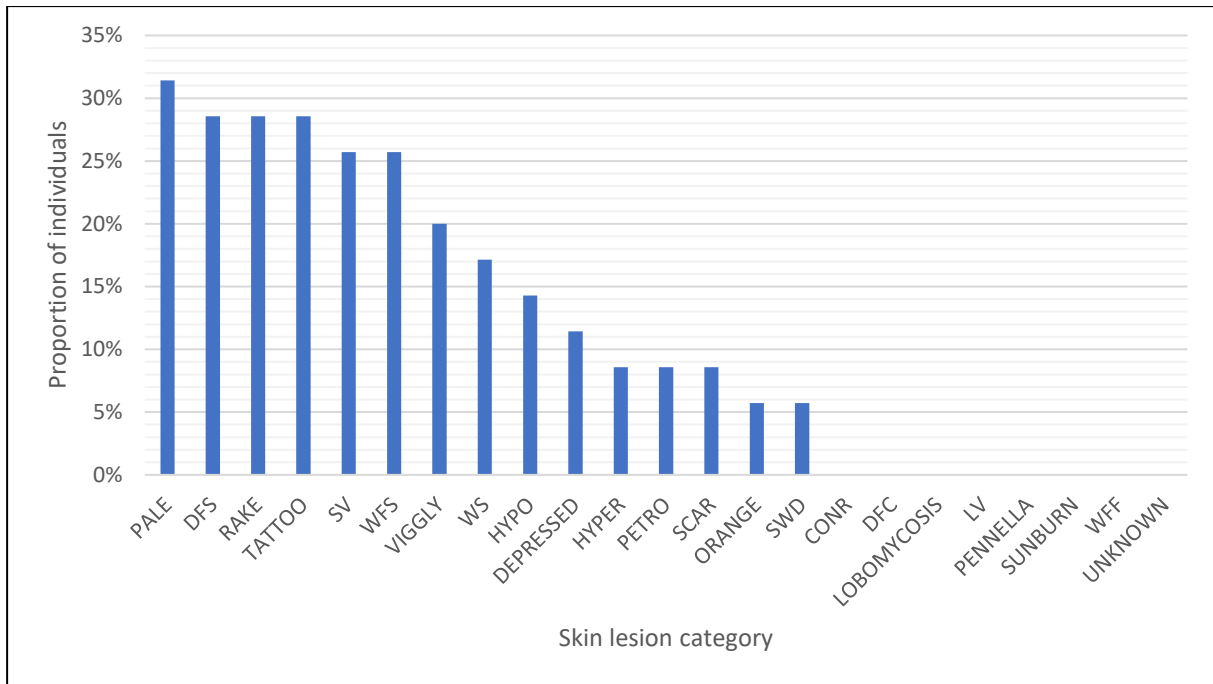


Figure 10. Prevalence of skin lesions in sample.

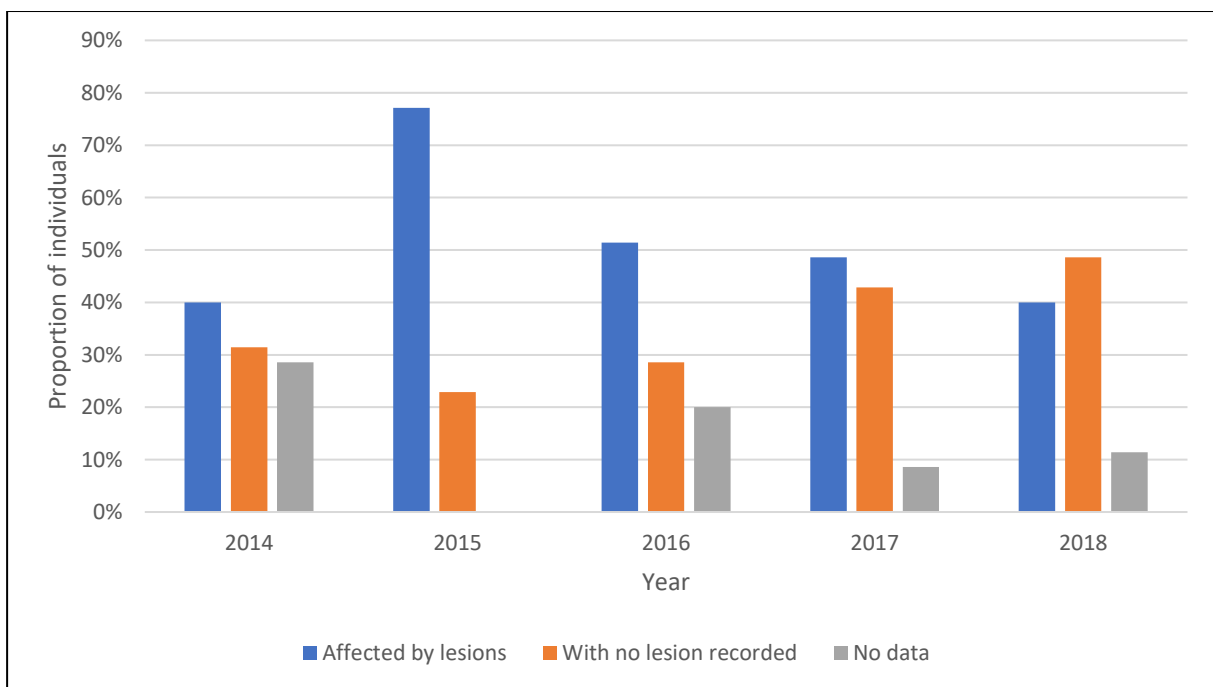


Figure 11. Proportion of individuals affected by skin lesions through years.

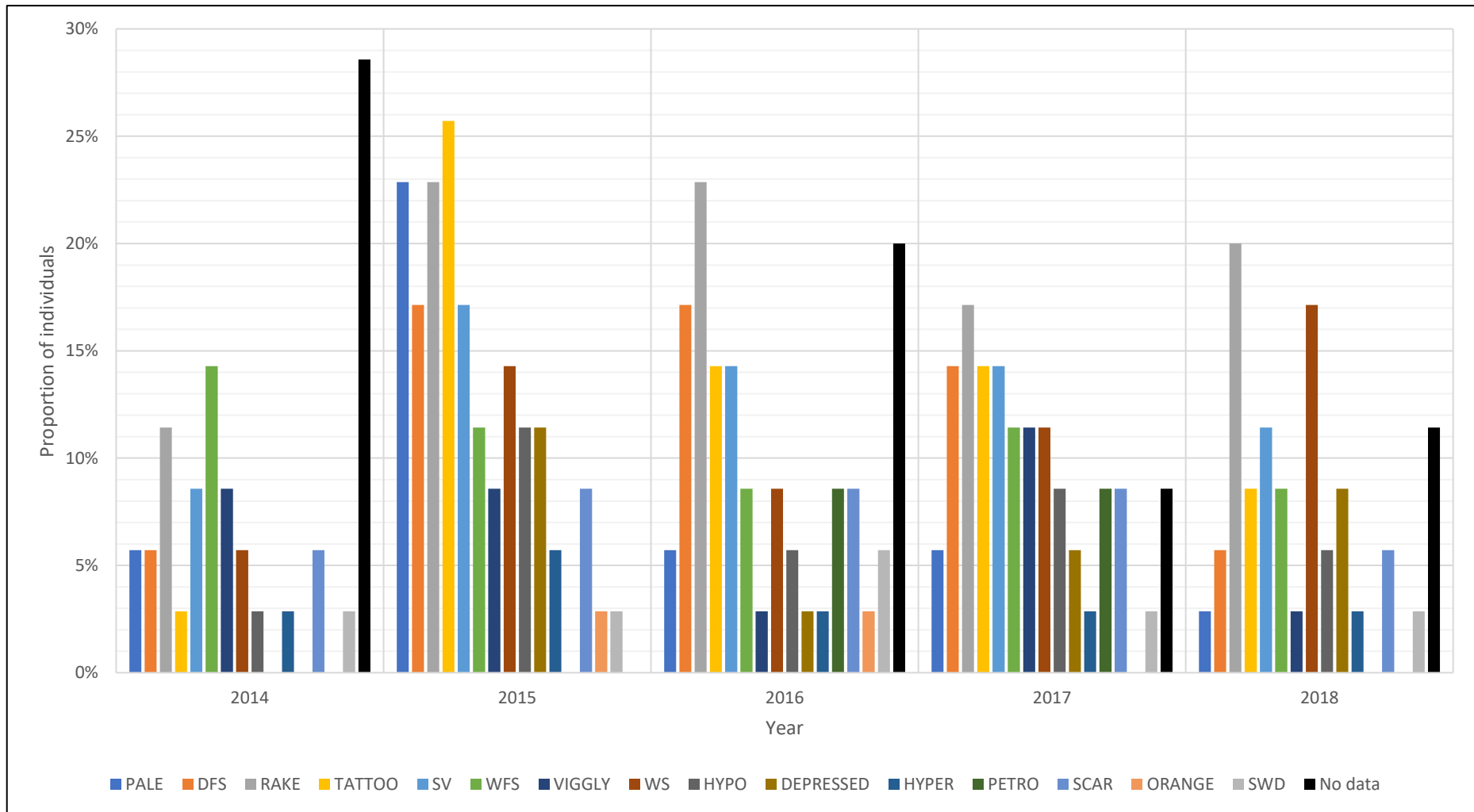


Figure 12. Prevalence of skin lesions in sample through years.

4.4.2. Co-occurrence of different skin lesion categories

During the five-year period, 6 dolphins (17.14%) were affected by one skin lesion type, while 23 dolphins (65.71%) were affected by more than one type of lesion (Figure 13 and Figure 14): 4 individuals (11.43%) were affected by 2, 8 individuals (22.86%) by 3, 4 individuals (11.43%) by 4 and four individuals by 5, 2 individuals (5.71%) by 6, and 1 individual (2.86%) by a maximum of 8 different types of lesions.

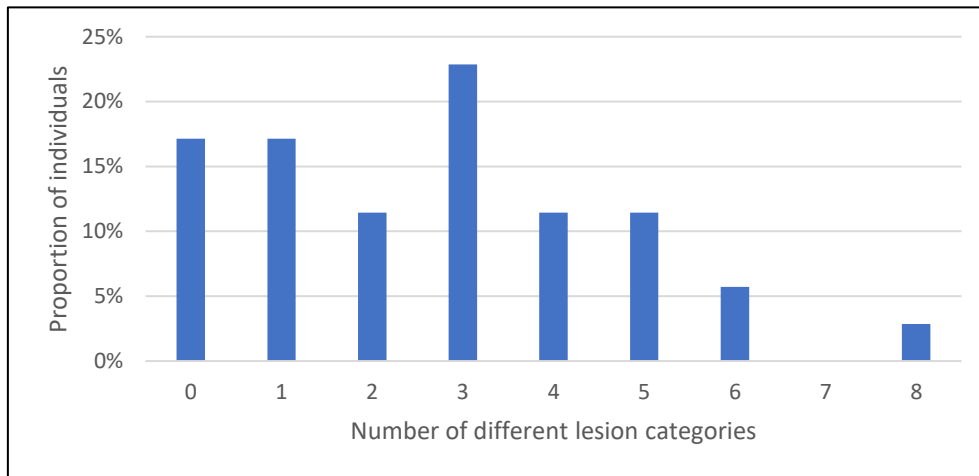


Figure 13. Proportion of individuals that were affected by 0 to max 8 different lesion categories in the whole study period.

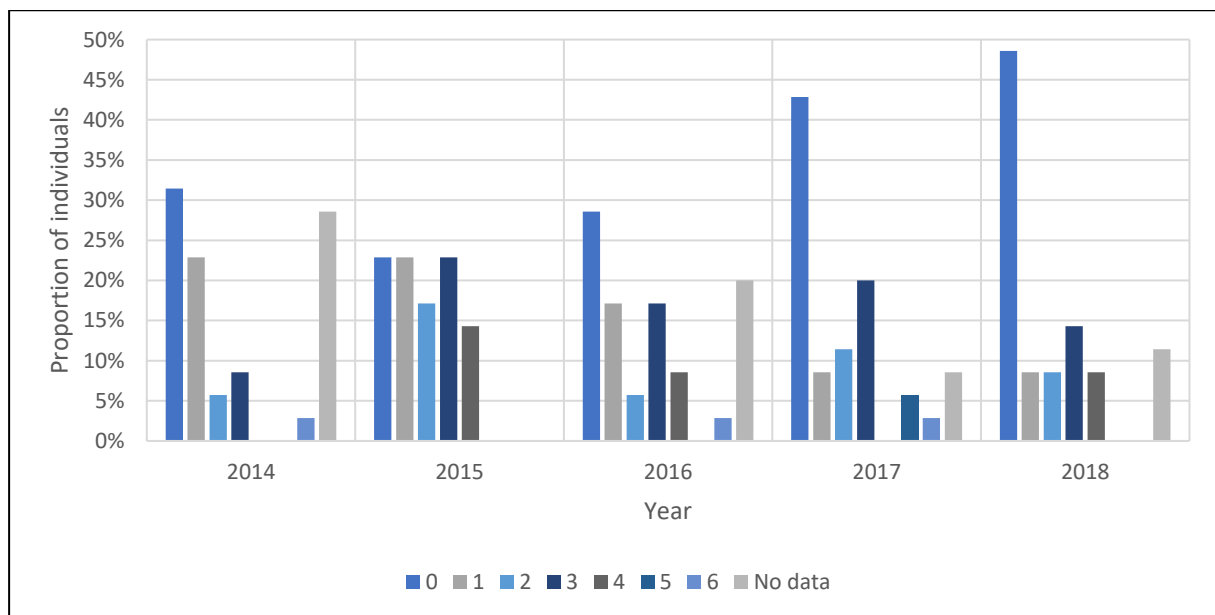


Figure 14. Proportion of individuals that were affected by 0 to max 6 different lesion categories in each year.

The analysis of potential association among lesion categories did not reveal any significant association. The dendrogram showing clustering of lesions recorded in sampled individuals at any point in time during the five-year study period (as shown in Table 3) and the modularity for cutoffs at different HWI values are shown in Figure 15. The cophenetic correlation coefficient of 0.759 was just below the threshold of 0.8 which is considered to indicate a good representation of association index matrix on a dendrogram. Likewise, the modularity was overall low with peaks just above 0.1, meaning there was no concrete grouping of lesions in the sample. This might be due to a small sample size so any association between lesions could not be confirmed. Nonetheless, the HWI value of 0.311, at which the peak of 0.11 in modularity was recorded, was taken as a cutoff for clustering of lesions and the groups formed using this cutoff are marked with colors in the dendrogram. Within these four groups of lesions, the strongest associations were between WS and RAKE, TATTOO and WFS, PETRO and DEPRESSED, and ORANGE and SWD. Furthermore, SV was grouped with RAKE and WS, VIGGLY and PALE with WFS and TATTOO, and DFS with PETRO and DEPRESSED. The association indices of HYPO and HYPER and SCAR were below the cutoff value. CLEAN refers to individuals with no lesions recorded so it has no association to any lesion.

Rake mark associated lesions were recorded in 10 animals and WS were recorded in 6 animals, while both lesion categories were recorded in 5 of these animals. TATTOO lesions were recorded in 10 animals, WFS lesions in 9 animals, and both lesions were recorded in 5 of these animals. DEPRESSED was recorded in 4 animals and PETRO in 3 animals. Presence of both lesions was recorded in 2 of these animals. ORANGE and SWD lesions were each recorded in 2 individuals, while only one individual was affected by both lesions.

Out of 5 individuals affected by RAKE and WS, in one individual the two categories affected the same body sector throughout four study years, while in the other individuals these lesions were recorded on distant sectors. TATTOO and WFS lesions were associated in 5 individuals. Previous studies have shown that both TATTOO and WFS could be the appearance of a disease caused by the same agent, poxvirus and this might explain the association between the two lesions found in the present study. DEPRESSED and PETRO were both recorded in 2 individuals, but in both cases on distant body areas (on anterior peduncle dorsal and head in one individual, and on anterior dorsal and middle flank ventral of the opposite lateral sides in the other individual). Moreover, in both individuals DEPRESSED was observed one year before PETRO scars appeared. Therefore, it is apparent that these two lesions were not

associated and that the grouping of these lesions on a dendrogram might not be accurately represented. The presence of ORANGE and SWD was observed in only one individual, thus this grouping was deemed inconclusive.

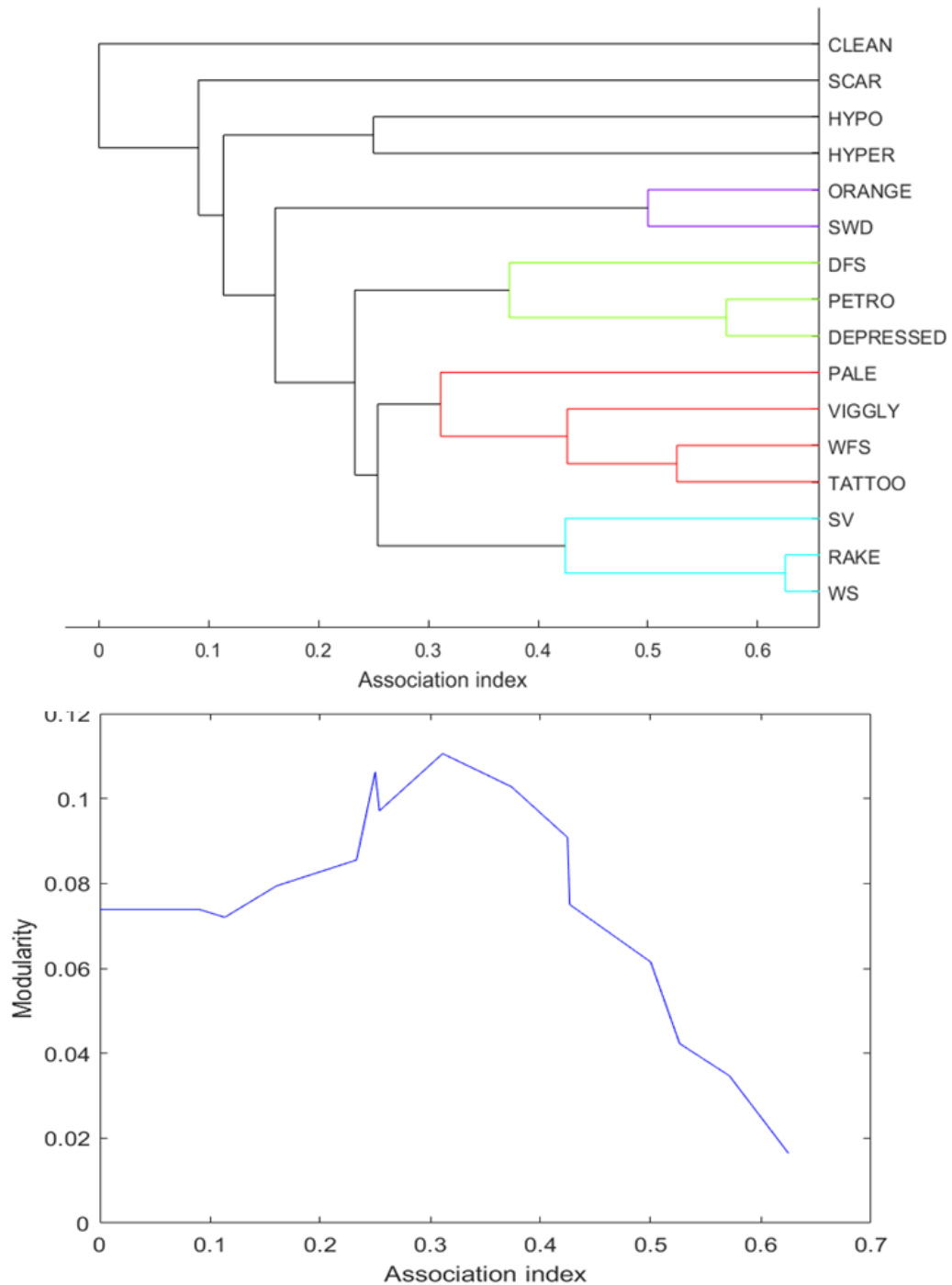


Figure 15. Hierarchical cluster analysis of fifteen skin lesion types recorded in sampled individuals at any point in time during the study period. The modularity for cutoffs at different HWI values are shown beneath the dendrogram. The HWI value of 0.311, at which the peak of 0.11 in modularity was recorded, was taken as a cutoff value for forming groups. The groups formed using this cutoff are indicated by colors in the dendrogram. “CLEAN” refers to individuals not showing any lesion type.

4.4.3. Skin lesion prevalence and extent in relation to affected body area

A total of 205 lesion occasions were recorded in 29 affected individuals, where one lesion occasion refers to one lesion category affecting one body sector of one individual, observed in one or more sightings in which the body sector was captured, provided that the lesion category was continual. Most lesions were recorded on fewer body sectors, while some were spread across greater area of individual's body. None of the lesions occurred exclusively on a particular body sector, except for ORANGE which was only recorded on the dorsal fin of two individuals (Figure 16). Likewise, none of the body sectors were affected exclusively by a particular lesion. Sea lamprey scars were recorded only on dorsal areas of the body, including sectors anterior, mid-flank, and anterior peduncle. Rake mark associated lesions were mostly observed on posterior peduncle, although few occasions were recorded on anterior peduncle and dorsal fin.

Ventral parts of anterior, middle flank and anterior peduncle, as well as the head, all had a high proportion of lesion occasions considering a limited visibility of these body sectors. Dorsal part of the middle flank had both great visibility and high occurrence of skin lesions. On the other hand, other sectors with high visibility, especially the dorsal fin, and dorsal parts of anterior and anterior peduncle had a lower occurrence of skin lesions. Prevalence of lesion occasions among body sectors are shown in Figure 17.

A detailed review of lesion categories and the greatest number of sectors affected simultaneously on the same date, within the same year, and throughout the whole study period for each individual is shown in Table 4. The individual that was affected by hyperpigmentation continually from 2014 until 2017, had at least eleven sectors affected by this lesion category, of which ten sectors were confirmed to be affected simultaneously on the same date (Figure 18). This individual was the only one with such an extent of hyperpigmented lesions, and the one with the greatest extent of any lesion found overall. Similarly, individual most affected by pale lesion had at least nine body sectors affected throughout the whole period, and at least seven sectors affected simultaneously (Figure 19). Individuals most affected by SWD and WS each had at least eight sectors affected overall, and six sectors affected simultaneously, while those most affected by SCAR and WFS each had at least seven sectors affected overall and seven (WFS) or six (SCAR) sectors affected simultaneously (Figure 20; Figure 21; Figure 22). A great number of lesions have been recorded on a smaller portion of the body, mostly one, two, or three sectors, such as examples of SV and RAKE shown in Figure 23 and Figure 24.

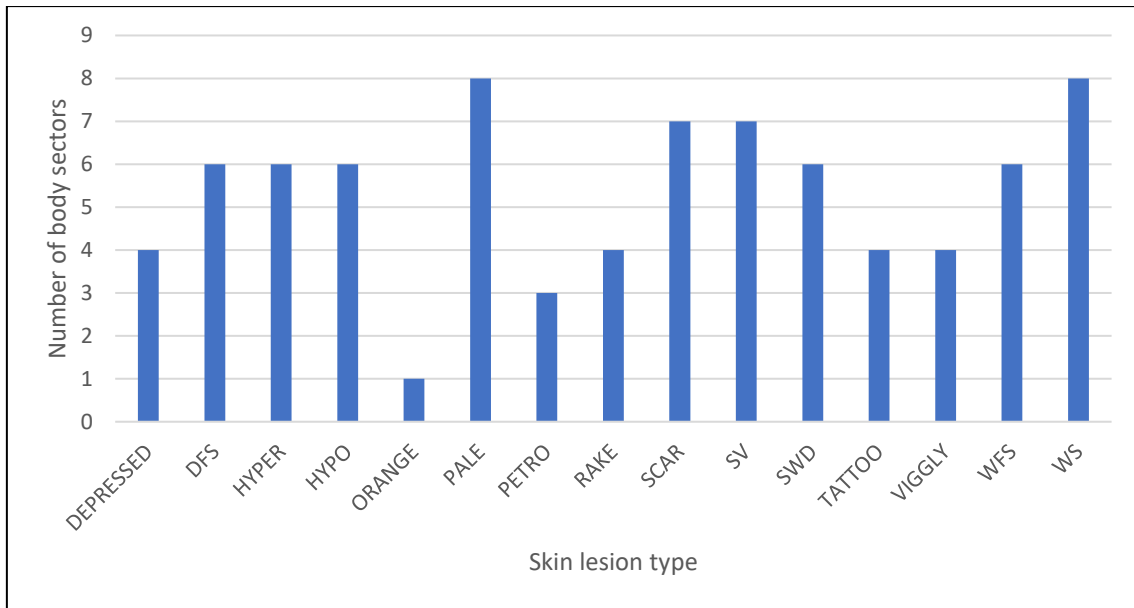


Figure 16. Number of sectors affected by each lesion type during the research period, irrelative to the lateral side.

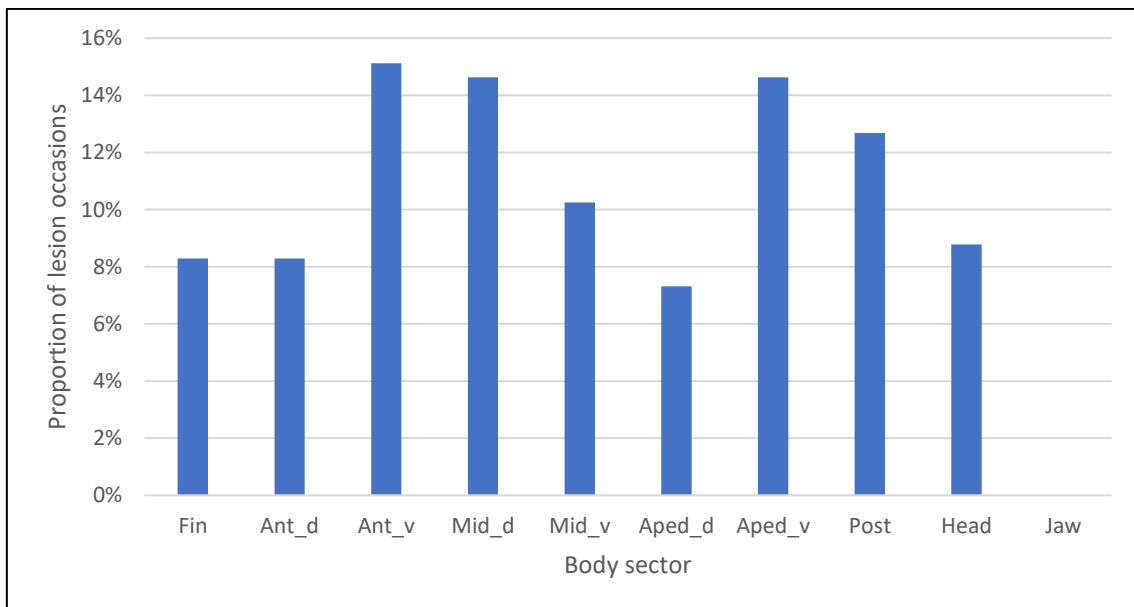


Figure 17. Prevalence of lesion occasions among body sectors during the whole study period. An occasion represents the presence of a lesion category on one sector independently of its extent, from its first observation onward, provided that it was continual.

Table 4. The extent of skin lesions among individuals. Sectors were counted with respect to the lateral side of the body. Column “Sectors affected” refers to a total number of sectors affected by any lesion. In the remainder of a table, first number refers to a maximum number of affected sectors recorded on the same date, the second number refers to a maximum number recorded within the same year, and the third number refers to a total number of affected sectors throughout the whole study period.

Dolphin ID	Sectors affected	DEPRESSED	DFS	HYPER	HYPO	ORANGE	PALE	PETRO	RAKE	SCAR	SV	SWD	TATTOO	VIGGLY	WFS	WS
Aquila	3		1;1;1								1;1;1					1;1;1
Babalina	10	1;1;1	2;2;2			1;1;1		2;2;2	1;1;1				1;1;1	1;1;2	3;3;3	
Bahor	5		1;1;1						2;2;2		1;1;1					2;2;2
Coco	1	1;1;1														
Dinko	8				1;1;1				2;2;2					1;1;1	2;2;3	3;3;3
Ferrero	11						1;1;1		2;2;2		3;4;5		1;1;1		1;1;1	6;6;8
Gabrijel	3										1;1;1			1;1;2		
Grof	6			1;1;1	2;2;2				2;2;2				2;2;2			
Hannahs09	1								1;1;1							
Ivano	7		1;1;1				2;3;3	1;1;1			1;1;1		1;1;1	1;1;1		
Kalanko	5								3;3;3			2;2;4				1;1;1
Knez	5			1;1;1							4;4;4					
Marko	3		1;1;1						2;2;2				1;1;1			
Matko	10		3;3;3						1;1;1	4;4;4			1;1;1		1;1;1	
Mijo	3				3;3;3											
Murluc	2	1;1;1					1;1;1						1;1;1			
Noah	1						1;1;1									
Raul	11					1;1;1	4;4;4		1;1;1			6;8;8				1;1;1
Roko	1		1;1;1													
Smokvas14	1													1;1;1		
Terjun	10		1;1;1				4;4;4			6;7;7						
Trastan	5									1;1;1	1;1;1				1;3;3	
Trata	9						7;8;9								1;1;1	
V_0710	3				2;2;2		1;1;1									
V_1411	6											5;5;6		1;1;1	1;1;1	
V_1416s14	11						1;1;1						1;1;1	3;3;3	7;7;7	
Zanzibar	13			10;11;11			1;1;1						2;2;2		1;1;1	
Zoran	8	1;1;1	1;1;1		3;3;3			1;1;1			3;3;3					
Zvir	6		1;1;1				2;3;3						2;2;2			



Figure 18. Bottlenose dolphin Zanzibar with various body sectors affected by HYPER. All photographs were taken on 8.6.2015.



Figure 19. Bottlenose dolphin Trata with various body sectors affected by PALE.



Figure 20. Bottlenose dolphin Raul with various body sectors affected by SWD.



Figure 21. Bottlenose dolphin V_1416s14 with various sector affected by WFS (indicated by white arrows) and VIGGLY (indicated by a yellow arrow). Photographs were taken on 10.4.2014.



Figure 22. Bottlenose dolphin Ferrero with various body sectors affected by WS.

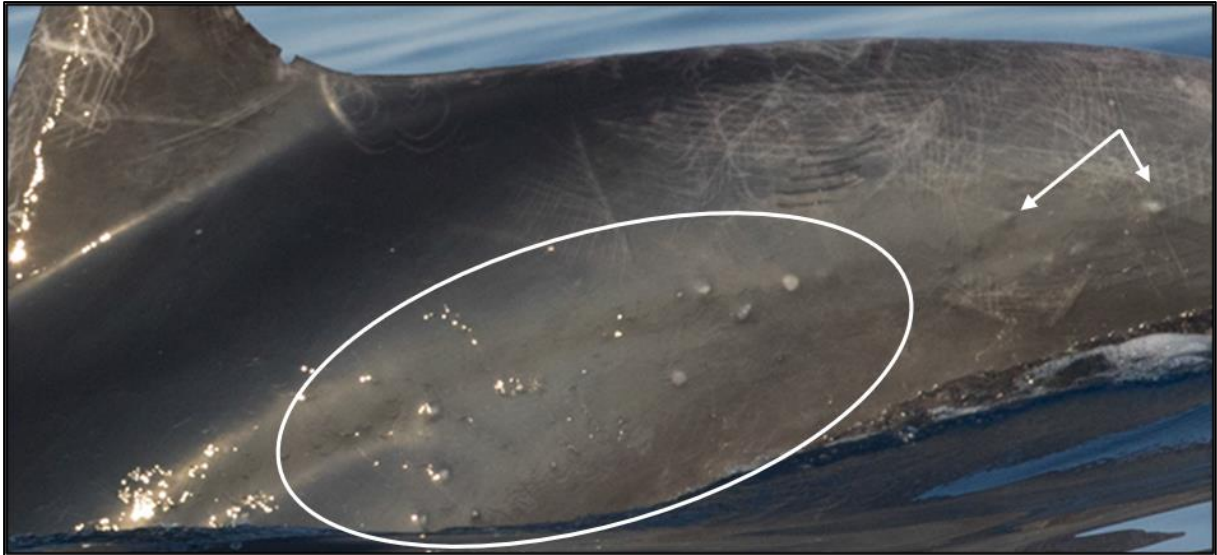


Figure 23. Bottlenose dolphin Knez affected by SV on 26.8.2017.




Figure 24. Bottlenose dolphin Kalanko affected by RAKE.

4.4.4. Dorsal fin as a proxy for lesions on the entire body

Dorsal fin was the most frequently captured body sector. This is expected since the effort is primarily made to ensure identification of individuals. Yet, with 8.29% of lesion occasions, it was among sectors least affected by skin lesions. Figure 25 shows the proportions of animals affected by lesions if a particular lesion was recorded on the dorsal fin, on any other body sector, and on both the dorsal fin and any other body sector. In most individuals, lesions were not present on the dorsal fin but were recorded on some other body sector. These include four individuals affected by DEPRESSED, ten individuals affected by DFS, three by HYPER, three by PETRO, two by SWD, ten by TATTOO, seven by VIGGLY, and nine by WFS. Very few lesions were recorded both on the dorsal fin and another sector of the body. These include one (20%) individual affected by HYPO, three (27.27%) by PALE, one (10%) by RAKE, and one (16.6%) by WS. ORANGE was the only lesion recorded only on the dorsal fins of two individuals.

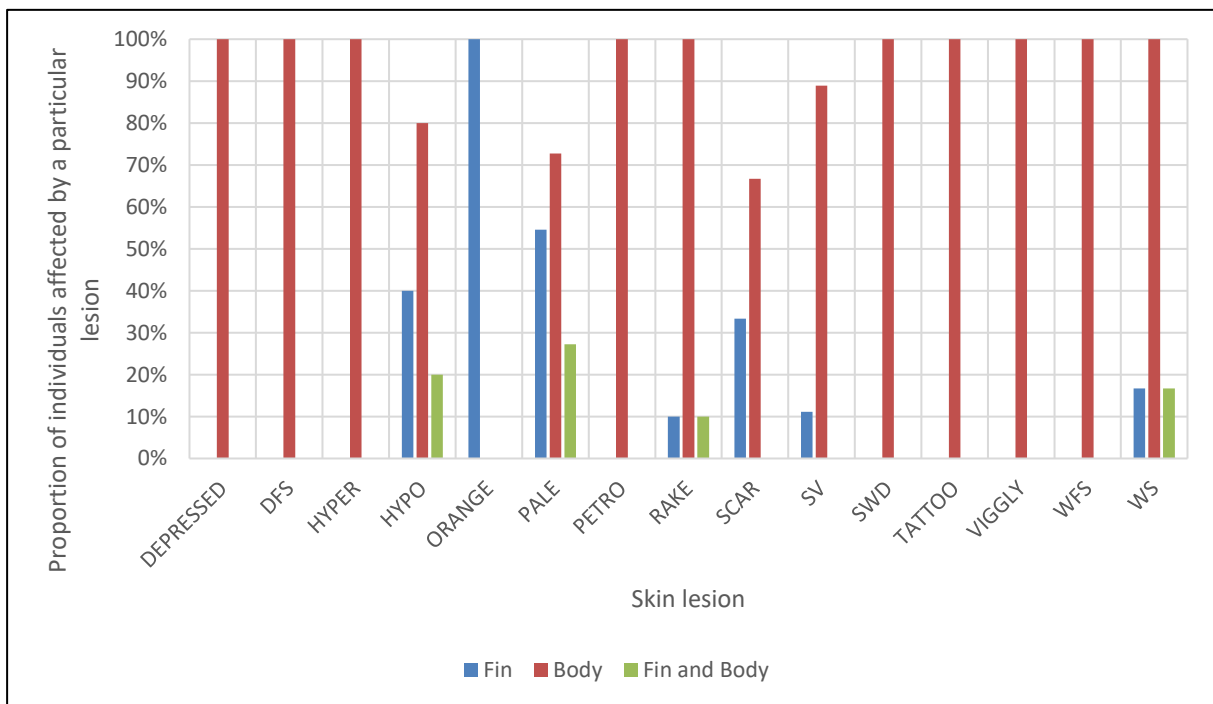


Figure 25. Dorsal fin as a proxy for lesions on the whole body. Series “Body” is showing proportion of animals with a particular lesion recorded on the body sector other than the dorsal fin, irrelative to the lesion being recorded on the fin. Likewise, series “Fin” is showing proportion of individuals with a lesion recorded on the dorsal fin. Series “Fin and Body” is showing proportion of individuals with a lesion recorded both on the fin and another body sector.

4.4.5. Skin lesion progression, duration, and healing rate

Healing was observed for a total of 49 out of 205 (23.9%) lesion occasions. Number of skin lesion occasions in the sample and numbers and proportions of occasions with observed healing are shown in Figure 26. None of the occasions of depressed and sunken, hyperpigmented lesions, healing wound scars and white spots have healed during the study period. On the other hand, both occasions of orange patches have retreated during the study period and pale lesions retreated in more than 70% of occasions. For other lesions, healing has been observed in less than 50% of occasions.

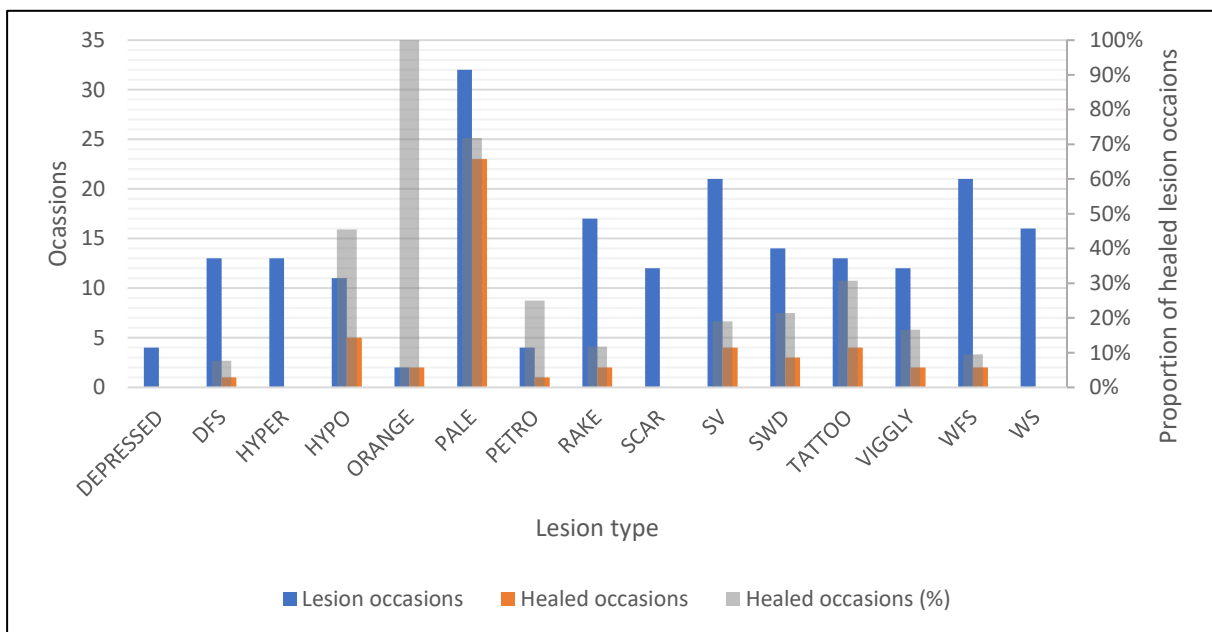


Figure 26. Total number of skin lesion occasions in the sample and numbers and proportions of healed occasions.

For all lesions that were captured in photographs on multiple encounters, duration was calculated as the number of days between the first and the last capturing. When healing of a lesion was not recorded, the duration of lesion occasion was calculated as the number of days from the first until (and including) the last date when the respective sector was captured on photographs and continually affected by the lesion. Since the affected body sector was not visible afterwards, in this way a minimum duration of each lesion occasion was calculated. Lesions recorded in only one sighting were not included in this analysis. To show the span of minimum durations, a boxplot shown in Figure 27 was created. In the boxplot, a number in parentheses near the lesion category indicate the number of occasions for which duration was calculated. If photographs of individuals or their affected body sectors and thereby lesions were not available in consecutive years, but were still affected when recaptured, those lesions were

considered continuous if present on the same sector, unless significant differences have been noticed.

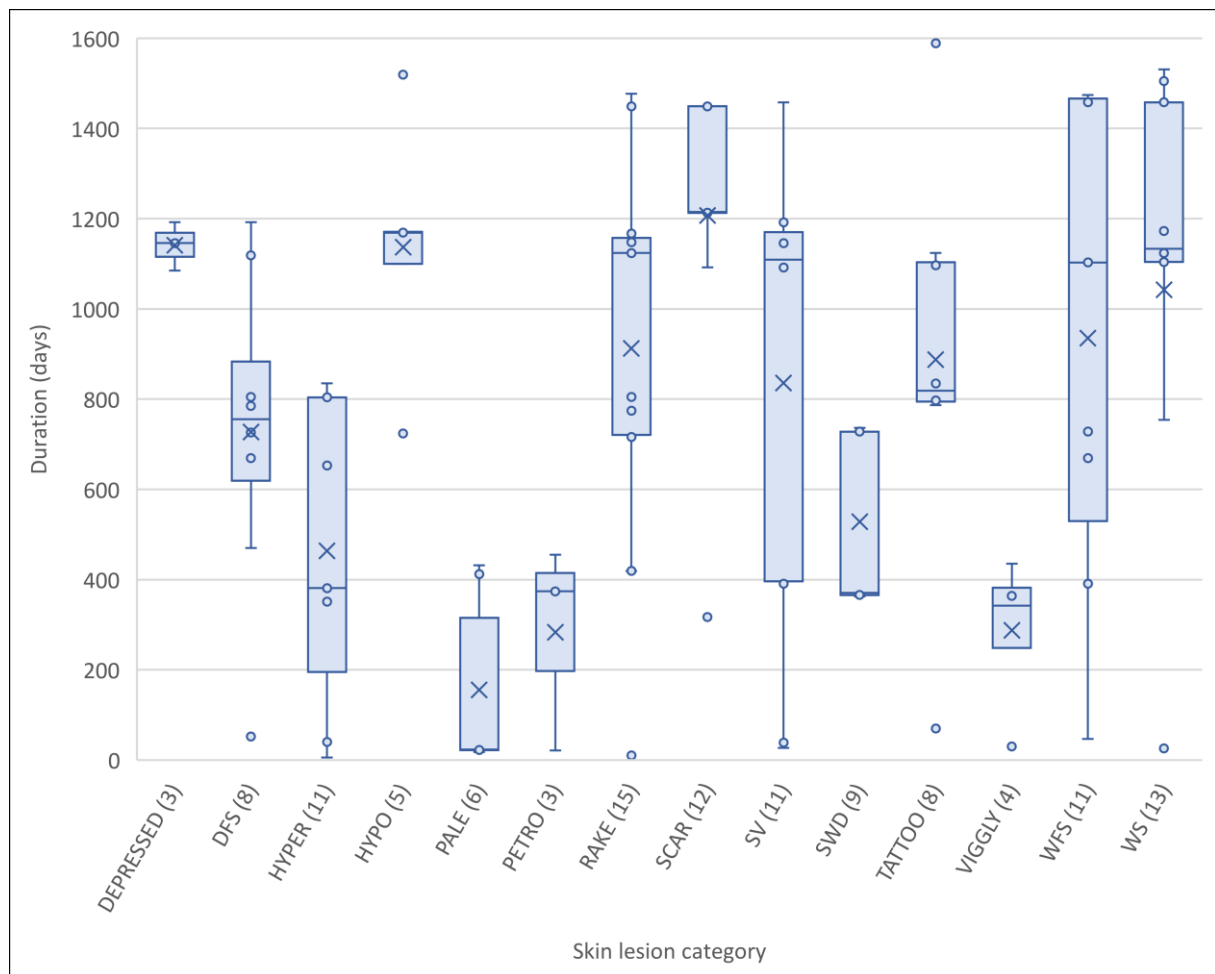


Figure 27. Minimum durations of lesions for which healing was not recorded. Numbers in parentheses indicate how many occasions were included in the analysis. The duration was calculated as the number of days from the first until the last sighting when the lesion was continually recorded. Thus, lesions recorded in only one sighting are not shown in the boxplot. The “box” shows where the middle portion of the data is and is defined by the first and the third quartile (25% and 75% marks). Circles represent the occasions, while those outside of the “box” and “whiskers” indicate outliers, or the extreme values. A line within the box indicates the median, while symbol “X” indicates the average.

For lesion occasions which have healed throughout the research period, a minimum duration has been calculated and, when possible, the time span in which it has healed (a maximum possible duration) (Figure 28). Here, the minimum duration refers to the time span between the first and the last date when a particular lesion was present on the sector, while the maximum duration refers to the time span between the last date prior to the first observation of the lesion, when the same sector was captured unaffected, and the first consecutive date when it was again captured, and the lesion was no longer present. Nevertheless, out of 49 healed occasions, 42 were captured only in one encounter before they have healed. The associated

body sectors of 22 such occasions were not captured prior to becoming affected, thus neither a minimum duration, nor time span in which it could have healed could be calculated. For remaining 20 occasions, a minimum duration remained unknown (set to 1 day in the graph), but the time span during which it has healed was calculated. Moreover, only a minimum duration could be calculated for additional four occasions since the affected sector was not captured prior to becoming affected but was captured with the lesion in multiple encounters. Those were occasions of RAKE (419 days), SWD (371 days), TATTOO (70 days), and WFS (693 days). Finally, both minimum duration and the time span could be calculated for remaining 3 occasions (one DFS, one PALE, and one PETRO). For DFS, the time span of possible duration was between a minimum of 52 and a maximum of 446 days, between a minimum of 18 and a maximum of 407 days for PALE, and a minimum of 426 and a maximum of 1,160 days for PETRO. The greatest number of occasions for which the time span could be determined belonged to the lesion category PALE (13 occasions), and the span of those durations are shown in the boxplot next to the line chart.

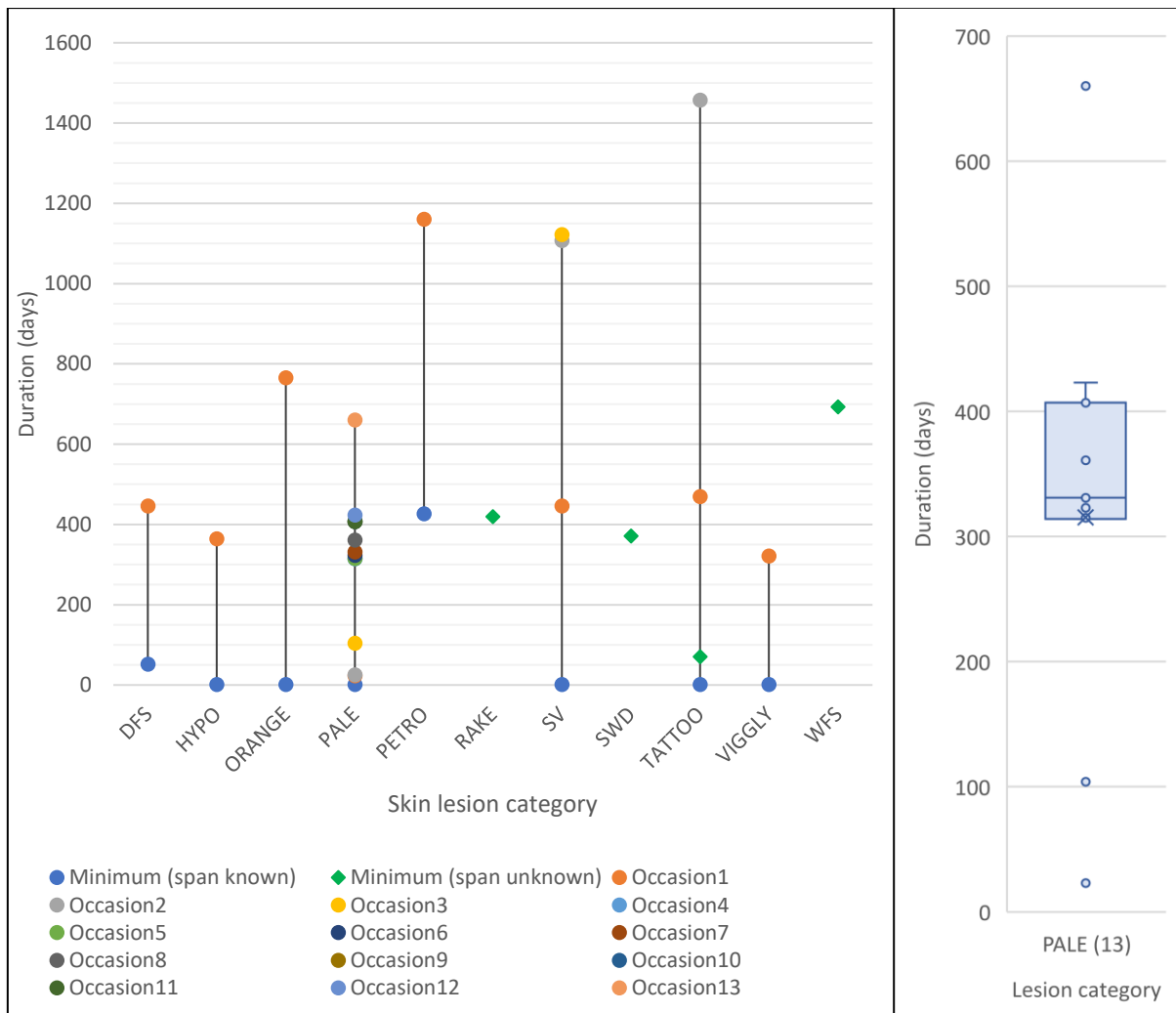


Figure 28. A minimum duration of lesion occasions and a time span during which they have healed. Minimum duration refers to the number of days between the first and the last capturing date, and the time span refers to the number of days between the last capturing date before it has appeared, and the first capturing date when it was no more present. Label “Minimum (span known)” includes occasions for which the time span could have been calculated, while label “Minimum (span unknown)” shows four occasions for which only minimum duration was calculated. Boxplot on the right shows the span of durations of PALE occasions. Circles represent occasions and the “box” indicates where the middle portion of the data is. A number in parenthesis indicate how many occasions were included.

Maximum possible duration of a single healed DFS occasion was calculated to 446 days (Figure 29), while all but one unhealed DFS lesion occasions lasted longer than 470 days. Similarly, a single healed HYPO occasion lasted between 1 and 364 days (Figure 30, upper images), however, another body sector of the same individual remained affected (Figure 30, bottom images) and additional 5 unhealed occasions lasted longer than 600 days (i.e., occasion shown in Figure 31). Healing of VIGGLY was recorded in one occasion and within one year from appearing, while other, unhealed lesions lasted longer than 400 days. For a single healed rake mark associated lesion, only a minimum duration could be calculated and was 419 days, while 15 unhealed lesions mostly lasted for a minimum of two or more years (Figure 32, images

on the right). In most cases, TATTOO lesions lasted longer than two years (Figure 32, images on the left), while one of the two healed lesions healed within the two years' time. The span of possible duration of healed occasions of PALE were mostly between 1 and 407 days (Figure 33), while unhealed PALE lesions have mostly been captured continually for up to one year only. A single healed PETRO scar has lasted between 426 and 1,160 days, while for those of which healing was not recorded, images were not available after 432 days or less. Both a maximum duration of healed SV and a minimum duration of most unhealed SV was between 400 and 1,200 days (Figure 34 and Figure 35).

Overall, the longest duration was recorded for the unhealed TATTOO occasion which lasted for a minimum of 1,589 days without change in the appearance, followed by the unhealed occasions of WS and HYPO which lasted for a minimum of 1,531 and 1,519 days, respectively (Figure 36). Another occasion of WS was recorded over 1,505 days, along with WFS which affected the same individual for 1,474 days (Figure 36). To the contrary, the shortest spans in which lesions have healed were recorded for two occasions of PALE on two individuals, which have healed within 23 and 25 days after appearing (Figure 33).

Depressed, scar and white spot, which did not heal in any occasion, were mostly recorded continually for more than three or four years (an example of SCAR is shown in Figure 37). On the other hand, hyperpigmented, which also did not heal in any occasion, was recorded in shorter span, mostly between a few months and two years. Overall, most unhealed lesions were recorded to last longer than a year, except for PALE, PETRO and VIGGLY which were recorded for 432, 455 and 435 days longest, respectively.

Moreover, most lesions have retained the appearance for years (an occasion of HYPO in Figure 31, TATTOO in Figure 32, TATTOO, WS, HYPO and WFS in Figure 36, SCAR in Figure 37), while the features of some lesions have visibly changed with the time. An occasion of RAKE shown in Figure 32 has become more prominent before fading away again, and the appearance of TATTOO occasions recorded throughout three and four years of the study period, has visibly changed, becoming paler and turning into whitish patches of the same size and shape (Figure 38, Figure 39 and Figure 40). Similarly, occasions of DFS shown in Figure 29 have lost their black rings prior to retreating completely. PALE lesion shown in Figure 33 have turned from smaller scattered lesions into one larger patch of pale area. In another individual, a PALE lesion has healed within a year of appearing but have reappeared a year later (Figure 41).




Figure 29. Progression of DFS on bottlenose dolphin Matko from its appearance until healing. 8.5.2016 the lesion was not there, 9.7.2016. the lesion was first recorded, 23.7.2016. a change in the appearance is noticeable (loss of the black ring), and 28.7.2017. the lesion is no longer visible.




Figure 30. Two occasions of HYPO on bottlenose dolphin V_0710. The dorsal fin was marked CLEAN on 9.8.2014. The presence of HYPO was first recorded on 7.6.2015. and has retreated by 8.8.2015. The presence of HYPO on the head was first recorded on 7.6.2015. and was still there on 8.8.2015.



Figure 31. Bottlenose dolphin Grof affected by HYPO from 2015 until 2018.



Figure 32. Bottlenose dolphin Babalina affected by TATTOO (left) and RAKE (right) throughout the four years of the study period. In 2018, VIGGLY appeared near TATTOO lesion.




Figure 33. Progression of PALE on bottlenose dolphin Trata. PALE was not present in 2014, and was first recorded on 18.5.2015. In the following encounter on 7.6.2015., a different patch has appeared, while on 12.6.2015. and in the following encounter it was no longer visible.



Figure 34. Bottlenose dolphin Kalanko affected by SV in 2016. SV retreated by 28.7.2018.



Figure 35. Bottlenose dolphin Zoran affected by SV throughout four years of the study period.




Figure 36. Bottlenose dolphins Ferrero, Bahor and Mijo affected by TATTOO, WS, HYPO, and WFS lesions which remained the same throughout the study period.



Figure 37. Bottlenose dolphin Matko affected by SCAR throughout the whole study period.




Figure 38. Bottlenose dolphin Zanzibar affected by TATTOO throughout three years of the study period. A change in appearance of the lesion is visible.




Figure 39. Bottlenose dolphin Grof affected by TATTOO over four years of the study period. A change in appearance of the lesion is visible.



Figure 40. Bottlenose dolphin Matko affected by TATTOO from 2015 until 2017. A change in the appearance is visible.




Figure 41. Bottlenose dolphin Terjun affected by PALE.

5. Discussion

In this study, the prevalence of skin lesions was found to be 82.86%. However, these results may not represent the prevalence of lesions in the bottlenose dolphin community in the Vis study area since the sample size was reduced after applying the sampling criteria. As these results reflect only the visible areas of the body, while the presence of lesions on the rest of the body remains unknown, they represent a minimal prevalence of skin lesions among the studied individuals. Moreover, the visibility of the body areas of the respective animals may differ significantly over the years, thus biasing the results. Because the study was conducted on wild, free-ranging animals, most individuals were not encountered in each consecutive year. Furthermore, animal behavior and surfacing patterns, such as approaching to or distancing from the boat, breaching, or exposing only the blowhole and the dorsal areas, the number of photographs taken, and weather conditions can all affect the quantity and quality of the photo-identification data. For this reason, photographs of identified individuals may not be available for all study years, or photographs may not be available for all body areas, or they may be available but of insufficient quality for analysis. On the other hand, some individuals are encountered regularly, even multiple times within a year, and consequently, the dataset for these animals could be larger and more informative. In this sense, significantly more photographs were taken overall in 2015 than in other study years, which resulted in having more good quality photographs that could be used for this study and photographs that captured larger area of the bodies. Furthermore, good quality photographs were taken of all animals in the sample that year, and more dolphins were found to be affected by skin lesions, but also more lesions overall were visible in the photos.

In contrast to the study conducted between 2002 and 2006 in the Northern Adriatic by Van Bresselem et al. (2009), in which tattoo lesions were found in 0% of the 80 individuals examined, in the present study tattoo-like lesions were among the most common skin lesions in the sample, affecting 28.57% or 10 of 35 animals examined. Wilson et al. (1999) found a 41.4% prevalence of pale lesions in a sample of 58 animals from the Kvarnerić area, and here a prevalence of 31.43% was found. On the other hand, they found a 44% prevalence of dark lesions, while in the present study only 8.57% prevalence of hyperpigmented lesions was found. Since there were no example photographs of dark lesions in Wilson et al. (1999), a comparison with the hyperpigmented category in this study was not possible. Miočić-Stošić et al. (2020) found eight sea lamprey scars in five of 1,491 individuals encountered in North Dalmatia and Vis

archipelago, and in the present study, four sea lamprey scars were found in three of 35 individuals examined. As both studies examined individuals encountered in the Vis area, same two bottlenose dolphins found to be affected were reported, while in the present study, scars were found in one additional individual. Moreover, in Miočić-Stošić et al. (2020), the longest reported period during which the sea lamprey scars remained visible was 36 months on the bottlenose dolphin Ivano. Here, the sea lamprey scar on the same individual was recorded for only one year, which is consistent with their results since they included photographs from the additional year in the study.

Most animals were affected by more than one type of skin lesion. Hierarchical cluster analysis of fifteen skin lesion categories recorded in the studied individuals showed no significant association between lesion categories. Although modularity was low, taking the HWI value at which the modularity peaked as a cutoff for clustering of lesions formed four groups of lesions. Consistent with the literature, TATTOO and WFS showed some degree of association, along with VIGGLY and PALE. Previous studies have shown that both TATTOO and WFS could be the manifestation of the same disease caused by poxvirus. Moreover, VIGGLY also resembled the appearance of TATTOO in some cases. However, low modularity and cophenetic correlation coefficient, probably due to the small sample size, indicate poor representation of association indices in a dendrogram so these groupings were not considered significant. Thus, although some lesions may have shown some degree of association, these results were generally inconclusive.

Although the dorsal fin was the most frequently captured body sector, it was among the least affected by skin lesions. Most lesions that affected the body of an animal did not also affect the dorsal fin, except for one animal that was affected by HYPO, three animals affected by PALE, one affected by RAKE, and one affected by WS on both the fin and another sector. A high proportion of lesions that affected another body sector but not the fin suggests that the dorsal fin is not a reliable representative of the presence of skin lesions on the entire body and cannot be used as a proxy for lesion prevalence in the sample or population.

Data on the prevalence of skin lesions were used to evaluate whether any of the external conditions could be used as an indicator of a compromised fitness in the population. Some studies reported that tattoo lesions could be a good indicator of the general fitness of cetaceans, since their occurrence in captive animals has been associated with their general health and stress levels. Here, 28.57% or 10 individuals were affected by tattoo-like lesions, and other dolphins were affected by DFS and WFS, which might also be a manifestation of the same disease. The

most common lesion category was PALE, which affected 31.43% or 11 individuals, and in most occasions healed within one or two years. Although the possible cause of these lesions remains unknown, they could be caused by herpesvirus according to Hart et al. (2012). Since the cause of these lesions remained unknown, it is uncertain whether some of them are stages of a single disease or different disorders. Rake mark associated lesions and small vesicular lesions were also observed in more than 25% of individuals. All observed lesions suggest that certain skin conditions are present within the Vis community, however additional data and diagnostic studies are needed to evaluate their potential to imply the fitness of the population.

Furthermore, DEPRESSED, RAKE, SCAR, WS, and WFS have mostly shown to be long-lasting and unchanged lesions and could be used as secondary markings to identify individuals. On the other hand, some lesions of TATTOO, PALE, and DFS underwent a visible change in appearance. Van Bresseem et al. (2003) and Powell et al. (2018) reported that tattoo and tattoo-like lesions became light grey during healing, and Smith et al. (1983) reported that tattoo lesions became blanched, elevated and vesicular. The same change in color was found in three TATTOO occasions recorded in this study. Although a few occasions of VIGGLY featured tattoo-like lesions, further investigation is needed to test whether VIGGLY in white form was preceded by a black form and thus showing the progression of tattoo-like lesions, or whether these two forms of VIGGLY are not related in any way. Dark-fringed spots that lost the black ring retained the features of white-fringed spots. Further studies are needed to investigate whether such a change is more common.

Although useful for assessing the skin conditions on free-ranging bottlenose dolphins, the use of photo-identification has certain limitations. The most obvious is the unattainability of causation of recorded conditions, as well as the fact that only limited areas of the animals' bodies are accessible for analysis. Moreover, lesion categories must be clearly defined to distinguish between similar conditions and to avoid omitting lesions that might have various appearances. A clear definition is needed for the quality of photographs that can be considered reliable for different lesions, as large and obvious lesions (i.e., depressions and some scars) might be easily seen in photographs where a small lesion or only discoloration would not be noticed. If photographs are treated according to a single definition of quality, some photographs showing large lesions might be omitted, or if these photographs are analyzed, less visible lesions might be omitted. Another limitation could be subjective distinction of body sectors and estimation of their visible area, especially when the photographs are analyzed by an untrained

person. To assess the progression of lesions, photographs capturing the animal and its affected sectors should be taken regularly, especially for lesions that change within a year.

Further studies involving more individuals encountered in Vis archipelago area over a longer research period should be conducted to provide more data on skin lesions within this bottlenose dolphin community, and to more thoroughly assess lesion progression, recurrence, and healing over time. In addition, less severe forms of small white dots, as shown in Gonzalvo et al. (2015), should be included in future studies, since some specimens were affected, but the lesions were less abundant and did not fit the description of small white dots specified for this study, and were not recorded. Moreover, Hart et al. (2012) reported different distributions of lesion types in populations from different areas, and this is also something that could be assessed in the Adriatic by comparing skin lesions in communities inhabiting the northern, central, and southern Adriatic.

6. Conclusion

The presence of 15 skin lesion categories was confirmed in 29 of 35 (82.86%) examined bottlenose dolphins. These were dark-fringed spots, depressed and sunken, healing wound scar, hyperpigmented, hypopigmented, orange patch, pale skin patch, sea lamprey scars, small vesicular, small white dots, rake mark associated, tattoo-like, viggly, white spots, and white-fringed spots. The most common category was pale skin patch, followed by dark-fringed spots, rake mark associated and tattoo-like lesions, all of which occurred in more than 25% of individuals. Due to the small sample size, none of the observed skin conditions can be considered as a baseline for assessing the fitness of the entire population. Hierarchical cluster analysis revealed no significant associations between lesion categories.

Considering their limited visibility, the ventral parts of the anterior, the middle-flank and the anterior peduncle, and the head all had a high prevalence of lesions, while the dorsal fin and the dorsal parts of the anterior and the anterior peduncle were visible more frequently but were less affected by lesions. Moreover, the dorsal fin was found to be a poor representative of the presence of skin lesions on the entire body and cannot be used as a proxy for lesion prevalence in the sample or population.

Throughout the study period, 24% of lesion occasions have healed, including 100% of orange patches, more than 70% of pale skin patches, and less than 50% of the occasions of other lesion categories. None of the depressed and the hyperpigmented lesions, scars, and white spots have healed. A change in appearance was noted for tattoo-like lesions, dark-fringed spots, and pale lesions. The duration of lesions varied. Depressed lesions, scars, white spots, and white-fringed spots were mostly recorded continuously for more than three or four years, and as such could be used as secondary markings for identifying individuals.

As there are few other studies relying on photo-identification data, this research is one of the first of its kind conducted in the Adriatic. It included the assessment of various lesion categories, their prevalence, longevity, and progression over time and may serve as a basis for future studies of skin conditions in bottlenose dolphins in the Adriatic Sea and the Mediterranean Sea in general.

7. References

- ACCOBAMS 2021. Estimates of abundance and distribution of cetaceans, marine mega-fauna and marine litter in the Mediterranean Sea from 2018-2019 surveys. By Panigada S., Boisseau O., Canadas A., Lambert C., Laran S., McLanaghan R., Moscrop A. (eds.) ACCOBAMS - ACCOBAMS Survey Initiative Project, Monaco, 177 pp.
- Bearzi, M., Rapoport, S., Chau, J. & Saylan, C. 2009. Skin Lesions and Physical Deformities of Coastal and Offshore Common Bottlenose Dolphins (*Tursiops truncatus*) in Santa Monica Bay and Adjacent Areas, California. *AMBIO: A Journal of the Human Environment*, 38, 66-71.
- Bertulli, C., Cecchetti, A., Van Bresseem, M.-F. & Van Waerebeek, K. 2012. Skin disorders in common minke whales and white-beaked dolphins off Iceland, a photographic assessment. *Journal of Marine Animals and Their Ecology*, 5, 29-40.
- Bossley, M. I. & Woolfall, M. A. 2014. Recovery from severe cutaneous injury in two free ranging bottlenose dolphins (*Tursiops* spp.). *Journal of Marine Animals and Their Ecology*, 7, 12-16.
- Cushman-Roisin, B., Korotenko, K. A., Galos, C. E. & Dietrich, D. E. 2007. Simulation and characterization of the Adriatic Sea mesoscale variability. *Journal of Geophysical Research*, 112, C03S14.
- Fortuna, C. M., Cañadas, A., Holcer, D., Brecciaroli, B., Donovan, G. P., Lazar, B., Mo, G., Tunesi, L. & Mackelworth, P. C. 2018. The Coherence of the European Union Marine Natura 2000 Network for Wide-Ranging Charismatic Species: A Mediterranean Case Study. *Frontiers in Marine Science*, 5, 356.
- Frleta-Valić, M. & Miočić-Stošić, J. 2021. Research report for 2020. Blue World Vis, Komiža, Croatia.
- Geraci, J. R., Hicks, B. D. & Aubin, D. J. S. 1979. Dolphin Pox - A Skin Disease of Cetaceans. *Canadian Journal of Comparative Medicine*, 43, 399-404.
- Gonzalvo, J., Giovos, I. & Mazzariol, S. 2015. Prevalence of epidermal conditions in common bottlenose dolphins (*Tursiops truncatus*) in the Gulf of Ambracia, western Greece. *Journal of Experimental Marine Biology and Ecology*, 463, 32-38.
- Grbec, B. & Precali, R. 2009. Baza podataka i pokazatelja stanja morskog okoliša, marikulture i ribarstva. Institut za oceanografiju i ribarstvo, pp. Temperatura, salinitet i gustoća morske vode.
- Hart, L. B., Rotstein, D. S., Wells, R. S., Allen, J., Barleycorn, A., Balmer, B. C., Lane, S. M., Speakman, T., Zolman, E. S., Stolen, M., McFee, W., Goldstein, T., Rowles, T. K. & Schwacke, L. H. 2012. Skin lesions on common bottlenose dolphins (*Tursiops truncatus*) from three sites in the Northwest Atlantic, USA. *PLoS One*, 7, e33081.
- Holcer, D. 2006. Dobri dupin (Bottlenose dolphin), *Tursiops truncatus* (Montagu, 1821). In: Tvrtković, N. (ed.) *Crvena knjiga sisavaca Hrvatske (Red book of mammals of Croatia)*. Zagreb: Ministry of Culture, State Institute for Nature Protection.

- Holcer, D. 2012. *Ecology of the common bottlenose dolphin, Tursiops truncatus (Montagu, 1821) in the central Adriatic Sea*. Doctoral thesis, University of Zagreb.
- Holcer, D., Fortuna, C. M. & Mackelworth, P. C. 2015. Adriatic Sea: Important areas for conservation of cetaceans, sea turtles and giant devil rays. *UNEP-MAP-RAC/SPA*. Tunis.
- Hupman, K. E., Pawley, M. D. M., Lea, C., Grimes, C., Voswinkel, S., Roe, W. D. & Stockin, K. A. 2017. Viability of Photo-Identification as a Tool to Examine the Prevalence of Lesions on Free-Ranging Common Dolphins (*Delphinus* sp.). *Aquatic Mammals*, 43, 264-278.
- Krstulović Šifner, S., Peharda Uljević, M., Dadić, V., Isajlović, I., Ezgeta, D., Marušić, I., Vlahović, V. & Bašković, D. 2009. *Opis ribolovnih resursa i preporuke za održivi pridneni ribolov u otvorenom moru srednjem Jadranu*, Institut za oceanografiju i ribarstvo.
- Leone, A. B., Bonanno Ferraro, G., Boitani, L. & Blasi, M. F. 2019. Skin marks in bottlenose dolphins (*Tursiops truncatus*) interacting with artisanal fishery in the central Mediterranean Sea. *PLoS One*, 14, e0211767.
- Maldini, D., Riggin, J., Cecchetti, A. & Cotter, M. P. 2010. Prevalence of epidermal conditions in California coastal bottlenose dolphins (*Tursiops truncatus*) in Monterey Bay. *Ambio*, 39, 455-462.
- Marasović, I., Ninčević, Ž., Kušpilić, G., Marinović, S. & Marinov, S. 2006. Long-term changes of basic biological and chemical parameters at two stations in the middle Adriatic. *Journal of Sea Research*, 54, 3-14.
- Miočić-Stošić, J., Frleta-Valić, M., Pleslić, G. & Holcer, D. 2019. Monitoring the abundance of common bottlenose dolphins in Vis archipelago (Central Adriatic Sea, Croatia). *World Marine Mammal Conference*,. Barcelona, Catalonia, Spain.
- Miočić-Stošić, J., Holcer, D., Dobrić, V. D., Pleslić, G., Počanić, P. & Radulović, M. 2015. Monitoring i zaštita dobrih dupina Viškog akvatorija. Final report. Blue World Vis, Vis, Croatia.
- Miočić-Stošić, J., Pleslić, G. & Holcer, D. 2020. Sea Lamprey (*Petromyzon marinus*) Attachment to the Common Bottlenose Dolphin (*Tursiops truncatus*). *Aquatic Mammals*, 46, 152-166.
- Penzar, B., Penzar, I. & Orlić, M. 2001. *Vrijeme i klima hrvatskog Jadrana*. Dr. Feletar, Hydrographic Institute of the Republic of Croatia - Split, Zagreb.
- Pettis, H. M., Rolland, R. M., Hamilton, P. K., Brault, S., Knowlton, A. R. & Kraus, S. D. 2011. Visual health assessment of North Atlantic right whales (*Eubalaena glacialis*) using photographs. *Canadian Journal of Zoology*, 82, 8-19.
- Pleslić, G., Rako-Gospić, N., Miočić-Stošić, J., Blazinić Vučur, T., Radulović, M., Mackelworth, P., Frleta-Valić, M. & Holcer, D. 2019. Social structure and spatial distribution of bottlenose dolphins (*Tursiops truncatus*) along the Croatian Adriatic coast. *Aquatic Conservation: Marine and Freshwater Ecosystems*, 29, 2116-2132.

- Pleslić, G., Rako Gospić, N. & Holcer, D. 2020. Bottlenose dolphins (*Tursiops truncatus*) in North Dalmatia, Croatia: Occurrence and demographic parameters. *Marine Mammal Science*, 37, 142-161.
- Pleslić, G., Rako Gospić, N., Mackelworth, P., Wiemann, A., Holcer, D. & Fortuna, C. 2015. The abundance of common bottlenose dolphins (*Tursiops truncatus*) in the former special marine reserve of the Cres-Lošinj Archipelago, Croatia. *Aquatic Conservation: Marine and Freshwater Ecosystems*, 25, 125-137.
- Pleslić, G., Tajmin, V., Rako-Gospić, N., Radulović, M. & Vučur, T. 2018. Longevity of common bottlenose dolphin (*Tursiops truncatus*) dorsal fin markings in the Adriatic Sea. In: Kružić, P., Caput Mihalić, K., Gottstein, S., Pavoković, D. & Kučinić, M. (eds.) *13th Croatian Biological Congress*. Croatian Biological Society, Poreč, Croatia.
- Powell, S. N., Wallen, M. M., Bansal, S. & Mann, J. 2018. Epidemiological investigation of tattoo-like skin lesions among bottlenose dolphins in Shark Bay, Australia. *Science of the Total Environment*, 630, 774-780.
- Ramos, E. A., Castelblanco-Martínez, D. N., Garcia, J., Arias, J. R., Foley, J. R., Audley, K., Van Waerebeek, K. & Van Bresseem, M. F. 2018. Lobomycosis-like disease in common bottlenose dolphins *Tursiops truncatus* from Belize and Mexico: bridging the gap between the Americas. *Diseases of aquatic organisms*, 128, 1-12.
- Russo, A. & Artegiani, A. 1996. Adriatic Sea hydrography. *Scientia Marina*, 60, 33-43.
- Sanino, G. P., Van Bresseem, M. F., Van Waerebeek, K. & Pozo, N. 2014. Skin disorders of coastal dolphins at Añihué Reserve, Chilean Patagonia - A matter of concern. *Boletín del Museo Nacional de Historia Natural*, 63, 127-157.
- Smith, A. W., Skilling, D. E. & Ridgway, S. 1983. Calicivirus-induced vesicular disease in cetaceans and probable interspecies transmission. *Journal of the American Veterinary Medical Association*, 183, 1223-1225.
- Stack, S. H., Currie, J. J., McCordic, J. A. & Olson, G. L. 2019. Incidence of Odontocetes with Dorsal Fin Collapse in Maui Nui, Hawaii. *Aquatic Mammals*, 45, 257-265.
- Taylor, J. S., Hart, L. B. & Adams, J. 2020. Skin lesion prevalence of estuarine common bottlenose dolphins (*Tursiops truncatus*) in North Carolina, with comparisons to other east coast study sites. *Marine Mammal Science*, 37, 127-141.
- Thompson, P. M. & Hammond, P. S. 1992. The use of photography to monitor dermal disease in wild bottlenose dolphins (*Tursiops truncatus*). *Ambio*, 21, 135-137.
- Townsend, F. I. & Staggs, L. 2020. *Atlas of Skin Diseases of Small Cetaceans*, Fort Walton Beach, FL, USA.
- Van Bresseem, M. F., Gaspar, R. & Aznar, F. J. 2003. Epidemiology of tattoo skin disease in bottlenose dolphins *Tursiops truncatus* from the Sado estuary, Portugal. *Diseases of Aquatic Organisms*, 56, 171-9.
- Van Bresseem, M. F., Simoes-Lopes, P. C., Felix, F., Kiszka, J. J., Daura-Jorge, F. G., Avila, I. C., Secchi, E. R., Flach, L., Fruet, P. F., du Toit, K., Ott, P. H., Elwen, S., Di Giacomo,

- A. B., Wagner, J., Banks, A. & Van Waerebeek, K. 2015. Epidemiology of lobomycosis-like disease in bottlenose dolphins *Tursiops* spp. from South America and southern Africa. *Diseases of Aquatic Organisms*, 117, 59-75.
- Van Bressem, M. F. & Van Waerebeek, K. 1996. Epidemiology of poxvirus in small cetaceans from the eastern south pacific. *Marine Mammal Science*, 12, 371-382.
- Van Bressem, M. F., Van Waerebeek, K., Aznar, F. J., Raga, J. A., Jepson, P. D., Duignan, P., Deaville, R., Flach, L., Viddi, F., Baker, J. R., Di Benedetto, A. P., Echegaray, M., Genov, T., Reyes, J., Felix, F., Gaspar, R., Ramos, R., Peddemors, V., Sanino, G. P. & Siebert, U. 2009. Epidemiological pattern of tattoo skin disease: a potential general health indicator for cetaceans. *Diseases of Aquatic Organisms*, 85, 225-37.
- Van Bressem, M. F., Van Waerebeek, K., Garcia-Godos, A., Dekegel, D. & Pastoret, P. P. 1994. Herpes-like virus in dusky dolphins, *Lagenorhynchus obscurus*, from coastal Peru. *Marine Mammal Science*, 10, 354-359.
- Wells, R. S. & Scott, M. 2009. Common bottlenose dolphin (*Tursiops truncatus*). *Encyclopedia of Marine Mammals*, 6, 249-255.
- Wilson, B., Arnold, H., Bearzi, G., Fortuna, C. M., Gaspar, R., Ingram, S., Liret, C., Pribanic, S., Read, A. J., Ridoux, V., Schneider, K., Urian, K. W., Wells, R. S., Wood, C., Thompson, P. M. & Hammond, P. S. 1999. Epidermal diseases in bottlenose dolphins: impacts of natural and anthropogenic factors. *Proceedings of the Royal Society B: Biological Sciences*, 266, 1077-83.
- Wilson, B., Thompson, P. M. & Hammond, P. S. 1997. Skin lesions and physical deformities in bottlenose dolphins in the Moray Firth: Population prevalence and age-sex differences. *Ambio*, 26, 243-247.
- Würsig, B. & Jefferson, T. A. 1990. Methods of photo-identification for small cetaceans. *Reports of the International Whaling Commission*, Special Issue 12, 43-52.
- Würsig, B. & Würsig, M. 1977. The Photographic Determination of Group Size, Composition, and Stability of Coastal Porpoises (*Tursiops truncatus*). *Science*, 198, 755-756.

Internet sources

<http://www.iucnredlist.org> (accessed 20.1.2021.)

Curriculum vitae

I was born in Pula in 1995. After finishing a general grammar school in 2013, I had enrolled in the undergraduate programme of Biology in the Faculty of Science of University of Zagreb, and in 2017 acquired a title Bachelor of biology. I have then enrolled in the graduate programme of Ecology and Nature Preservation in the same Faculty. During the study, I was a member of the Biology Students Association "BIUS" and have participated in several field trips with section for marine biology and section for education. I have participated in preparing and presenting workshops on marine biology for the public event "Night of Biology" organized by the Faculty of Science in several academic years. In 2017 and 2018 (June – September) I have worked in the diving center Draulik in Milna, island Brač, where I have assisted with helping the customers, handling and maintaining a diving equipment and boats, and assisting during the dive. In 2018 I have also occasionally worked as a skipper on small speedboats. In 2019 (June - September) I have volunteered as a researcher's assistant in the Blue World Vis association where I participated in boat-based surveys of marine mammals, in collecting the data, and in preparing, handling, and maintaining a research boat and the equipment. Since June 2020 I have been employed by the Blue World Institute of Marine Research and Conservation as an assistant for educational and promotional activities on the ECOSS project, and I have assisted with implementation of project activities, development of educational and promotional material, conducting fieldwork and data analysis. I am fluent in English (C1 level certificate, 2016) and am proficient in Microsoft Office (Word, Excel, PowerPoint) and Adobe Photoshop Lightroom. I have acquired a driving license (B category, 2013), a scuba diving license (CMAS R2, 2016), and a boating license (C category, 2018).